

AN ASSORTMENT OF PALAEOPATHOLOGICAL FINDINGS FROM THE ANTHROPOLOGICAL COLLECTION OF THE INSTITUTE OF ARCHAEOLOGY IN PRAGUE IN FUNDS OF THE NATIONAL MUSEUM

JAKUB LIKOVSKÝ

Department of Natural Sciences, Institute of Archaeology of the Czech Academy of Sciences, Letenská 4, 118 01 Praha 1, Czech Republic, e-mail: likovsky@arup.cas.cz

PETRA STRÁNSKÁ

Department of Natural Sciences, Institute of Archaeology of the Czech Academy of Sciences, Letenská 4, 118 01 Praha 1, Czech Republic

PETR VELEMÍNSKÝ

Department of Anthropology, National Museum, Prague, Václavské náměstí 68, 115 79 Praha 1, Czech Republic, e-mail: petr.veleminsky@nm.cz



Likovský, J., Stránská, P., Velemínský, P. (2005): An Assortment of Palaeopathological Findings from the Anthropological Collection of the Institute of Archaeology in Prague in Funds of National Museum. – *Acta Mus. Nat. Pragae, Ser. B, Hist. Nat.* 61 (3–4): 81–140. Praha ISSN 0036-5343.

In 1991, an assortment of palaeopathological findings on human skeletal remains, collected during several decades in the Department of Anthropology, later in the Department of Natural Sciences of the Institute of Archaeology of the Czech Academy of Sciences in Prague was transferred together with the anthropological collections to the Department of Anthropology of the National Museum, Prague. The Department of Anthropology was founded in the Institute of Archaeology in the year 1950. Foundations for the assortment of pathological findings on skeletal remains of past populations were laid by the founder of the department, RNDr. Jaromír Chochoř, CSc. (1926–1990) who primarily collected them as material usable in teaching students of prehistory in the Faculty of Philosophy of Charles University in Prague. Among the findings, the most frequent are degenerative, traumatic and inflammatory conditions. However, a series of unique findings is also involved in the assortment, among them the oldest case of tuberculosis in the Czech region dated into the Eneolithic and several findings of primeval trepanations. Also several examples of the so-called pseudopathologies are included in the presented assortment of findings. The palaeopathological diagnoses were newly revised and the findings were provided with new documentation. Individual pathological findings will now be united with residual parts of their skeletons from which they were once taken into the assortment of palaeopathological findings. It must be admitted, that by such arrangement, the assortment of palaeopathological findings will be dispersed but the newly compiled documentation makes it possible to better treat both the material and the palaeopathological findings which thus may be better used as educational, comparative and instructional material.

■ Anthropology, palaeopathology, pseudopathology, intentional interventions, trepanation, tuberculosis.

Received October 10, 2005

Introduction

The assortment of palaeopathological findings on human skeletal remains collected through the 1980s in the Department of Anthropology of the Institute of Archaeology of the Czech Academy of Sciences in Prague was transferred in 1991 to the Department of Anthropology of the National Museum. The findings were not systematically selected for their assortment of pathologies and the palaeopathological resources of that time were limited compared to those available today. Despite that, the assortment includes a broad spectrum of pathological states and a number of cases are remarkable – for the proper pathological changes, their extent and for dating the finding with concrete sort of pathology.

Palaeopathological diagnoses were revised and consulted with a number of specialists in clinical medicine, detailed photographic documentation and – if necessary – X-ray pictures of the findings were made.

The aim of the present study is to elucidate the circumstances in which the assortment of palaeopathological findings was formed in the Department of Anthropology of the Institute of Archaeology, to trace the fate of findings and to treat the nature of the completed assortment. The present paper may also serve as a catalogue of findings involved in the assortment, since not all of them were published in the past or incorporated into the survey of known palaeopathological findings (Hanáková and Vyhnánek 1981).

Department of Anthropology in the Institute of Archaeology and the origin of the assortment

The Department of Anthropology in the former State Institute of Archaeology was founded by RNDr. Jaromír Chochoř, CSc. (1926–1990) in January 1950. It was the first workplace specializing in the study of prehistoric and historic human skeletons or burnt residues obtained from archaeological investigations (Blajerová and Šaldová 1986).

The former Department of Anthropology was initially located in the library of the institute, later a space was found in the former hotel “Modrá Hvězda” in Újezd street in Prague. There it stayed until 1964, when it was moved to the seat of the Institute of Archaeology in Letenská Street, the Lesser Town in Prague – in the so-called Krocovský House – into the former horse stable. In this space it resides today as a part of the Department of Natural Sciences, which besides anthropology and paleopathology includes archaeozoology, archaeobotanics and archaeogenetics.

Until the mid 1960s the depositories were located in the already mentioned “Modrá Hvězda” and in “Ungelt” in the Old Town of Prague. The anthropological material was later moved into the space of the former Franciscan Convent at the Holy Trinity Church in Slaný and remained there until the early 1980s. The buildings of former schools in Hněvkovice close to Humpolec and in Obora served as additional depositories. In 1991 the material was transferred from the Department of Anthropology into the collections of the National Museum in Prague. In the early 1990s, the material was moved into subterranean halls beneath the Prague Castle, then into the space of former winter stables of the Czechoslovak State Circuses in Prague – Horní Počernice in whose neighbourhood new modern depositories for the National Museum – Museum of Natural Sciences were built in the late 1990s. The material is currently deposited there.

An impetus to collecting the pathological findings was given in the time when J. Chochol began to read lectures on principles of anthropology to students of prehistory in Faculty of Philosophy of Charles University in Prague. Partially due to the above-mentioned repeated moving of the material basis and to the isolation from the Department of Anthropology, the selection of findings into the assortment of palaeopathological findings has not been systematic. The assortment was assembled in the Department of Anthropology of the Institute of Archaeology mainly by J. Chochol but it involves many findings from burial grounds which were anthropologically treated by other members of the department at that time (M. Blajerová, H. Hanáková, M. Stloukal) and it also involves findings from skeletal collections treated after the death of J. Chochol (P. Stránská, V. Černý); however, all those are derived from older archaeological investigations.

Resources of palaeopathological diagnostics

Palaeopathological changes found in skeletons from prehistoric or historic periods are at the present time treated in a very rich literature ranging from detail monographs to innumerable amounts of descriptions of individual cases (worldwide, more than 26,000 works appeared through the year 1998). This field of study is constantly developing and the diagnostic resources are broader thanks to a continuously richer cooperation with departments of clinical medicine. Consequently, the spectrum of pathological states that may be identified in the skeletal material is also broader. Beside the computer tomography (CT), which has already been

used for years at assorted findings, densitometry was recently added to the group of X-ray examination methods. This clinical method, which is used for diagnostics of osteoporosis, came to be applied in paleopathology for investigating bone mineral density in groups of archaeological skeletons. The aim is to get insight into the trends of development of bone mineral density: it should help to understand the reasons why osteoporosis is progressing among populations in the present time. This problem is currently being studied in several centres, mostly in Europe (Ekenman and al. 1995, Lees and al. 1993, Mays and al. 1998, Mays 1999, Poulsen and al. 2001). Another clinical method, endoscopy, which is used mainly for examination of the digestive tract, came to be used in palaeopathology in 1975, primarily for investigating mummies (first by Manialawi and al. 1978). In our country, endoscopy is used for examination of intracranial structures and anomalies (Likovský and Drda 2003, Velemínský and al. 2005).

Microscopy, which requires much exacting work, is not often used in palaeopathology; however, modern modifications, e.g. scanning electron microscopy and laser scanning confocal microscopy (Šefčáková and al. 2001, Němečková and Strouhal 2003) enhance the accuracy of some diagnoses, mainly at sites of tumour lesions.

The most modern diagnostic branch – molecular genetics – is usable mainly in detecting originators of infectious diseases. Detection of tuberculosis and leprosy is already widespread in the world (in our country Strouhal and al. 2002); the method should be helpful in diagnostics of diseases which do not cause morphological changes in bones and which may be estimated from the circumstances of discovery relating e.g. to pestilence (Guiyoule and al. 1994).

With the development of palaeopathological diagnostics it is possible to differentiate the viewpoints from which the study is approached: we speak then about geographic, demographic and historical palaeopathology (Vyhnánek 1999). Palaeopathology of populations studies and evaluates the frequency and – if desired – the intensity of chosen pathologic states in dependence on age and sex for all evaluable individuals in a firmly dated group. Palaeopathological casuistic describes in detail findings for only one individual, which is important with regard to circumstances of the archaeological finding.

The majority of the above-mentioned diagnostic methods are currently used in the Department of Natural Sciences of the Institute of Archaeology. A series of studies is being carried out in close cooperation with the Department of Anthropology of the National Museum in Prague. The joint studies use both densitometry and endoscopy thanks to cooperation with several clinical departments. The laboratory of archaeogenetics is part of the Department of Natural Sciences of the Institute of Archaeology, and beside the diagnostic methods that are presently under development (sex determination, genetic relationship) it is beginning to undertake palaeopathological diagnostics. In study of skeletal groups, emphasis is laid on treatment and evaluation with regard to population.

The assortment of palaeopathological findings of the Institute of Archaeology represents a collection of casuistics. In the time of gathering the pathologic findings to form the assortment, resources of palaeopathological diagnostics were rather limited in comparison with the present. Specialized palaeopathological literature, which could serve as a guide for comprehension, and interpretation of pathologic changes in the skeletal material was just beginning to appear. First works conceived in complex and modern style appeared only in the 1960s (e.g. Brothwell 1968); the whole-world Palaeopathological Association was only founded in the year 1973 (Strouhal 1998).

In the past, beside proper morphological estimation of a finding together with macroscopic discernment of abnormalities, the only auxiliary investigative method used was in fact the X-ray examination. Providing X-ray pictures was limited to selected findings; cooperation with clinical departments was minimal at that time.

J. Chochol mostly determined his palaeopathological diagnoses alone, and he also helped other members of the department with this task. Some pathological findings were evaluated by the radiologist prof. MUDr. Luboš Vyhnaněk, DrSc. (1928–1999), who – as one of few clinical physicians – was engaged also in palaeopathology. Unfortunately, due to an immense workload both in his own specialty of radiology and in his post as head of the radio-diagnostic clinic, and with regard to a vast cooperation with perhaps all anthropological investigators, he left behind a number of un-evaluated findings.

Characterization of the assortment of palaeopathological findings

Selection of findings into the assortment of palaeopathological findings was not systematic. Initially, the Department of Anthropology tried to save funds of material originating from older excavations, which were scattered over depositories in various regional museums (Blajerová and Šaldová 1986). This was followed by anthropological treatment of skeletal collections obtained from new excavations (Text-figs 1–3).

Representation of localities and individual periods or cultures is not balanced. The same may be said about the representation of various pathologic states. Sporadically represented is the Eneolithic (the Bell Beaker Culture and the Corded Ware Culture), the Bronze Age (Knovíz Culture and Únětice Culture), La Tène Period and Migration Period. Prevaingly represented are Early Medieval findings. Among the localities well represented are those where larger excavations were carried out in the time of collecting the assortment due to treating the material in a direct linkage to the Department of Anthropology of the Institute of Archaeology. For this reason, large parts of the assortment are pathological findings from Lahovičky, Libice nad Cidlinou and Stará Kouřim, together with the Early Medieval findings from Báň and from Nové Zámky in Slovakia.

The majority of palaeopathological findings are degenerative and traumatic changes, inflammatory changes docu-

mented in a series of illustrative findings and specific infectious diseases like tuberculosis, but the assortment includes also a series of congenital or developmental anomalies and dental defects. Among the intentional intercessions, beside several trepanations are also found amputations of extremities and dental mutilation (see below). Together with clear pathologic states a series of questionable findings was included into the assortment; in several cases the changes are rather post-mortal, some could also be classified as pseudopathologies.

The most important findings

Although the assortment of palaeopathological findings was not formed systematically, it includes a series of findings, which are interesting by proper pathological state, by extent of pathological changes or by dating.

One of the findings remarkable for its dating is the finding of spinal tuberculosis from the Corded Ware Culture from Vykletice (Chomutov district), No. Ao 4790 (Chochol 1970). Nowadays it stands as an example of the oldest evidence for this disease on the territory of Bohemia. Another example of tuberculosis comes from medieval Prague 2-Vyšehrad, No. Ao 8976 (Stránská 1990).

From the other diseases should be mentioned block of vertebrae due to Bechterew's disease, dating from Early Medieval Ages, from Prague Castle, No. Ao 901 (Blajerová 1979). The diffuse idiopathic skeletal hyperostosis (DISH) is represented by two illustrative examples, both dating from Middle Ages: No. Ao 5473 from Bílina (Teplice district) (Hanáková 1971) and No. Ao 6730a from Prague 2-Vyšehrad (Stránská 1990).

A series of finding of osteomyelitis is included in the assortment of palaeopathological findings (Text-fig. 4). Remarkable among them is an undated set of long bones consisting mostly of lower extremities No. Ao 6096 from Prague 1-Na Františku. A rare case is represented by finding of the sclerosing osteomyelitis of Garré from Prague 2-Vyšehrad, No. Ao 9103/XV dating from Middle Ages (Stránská 1990).

Traumatic changes involved in the palaeopathological assortment are numerous. Notable is the fracture of mandible at which a pseudo-arthritis was formed. The finding No. Ao 1558 dates from the Migration Period and comes from Lužec nad Vltavou (Mělník district). Formation of pseudo-arthritis is illustrated in a fracture of the forearm with the non-union in the middle of diaphysis of both bones in the forearm, No. Ao 1436, from Late Medieval from the Convent of St. Agnes in Prague 1. Among the changes of traumatic origin, interesting is the finding of knee luxation with a severe deformation of the distal end of the femur and of the proximal end of the tibia, with extensive secondary inflammatory changes. The finding No. Ao 3762 from Žalany (Teplice district) dates from 11th–12th century (Hanáková 1963).

Among the cranial traumata should be mentioned the finding of healed cut wounds and blunt injury of No. Ao 5432, found in the burial ground from Late Medieval up to



Text-fig. 1 Chrudoš Troníček, Jaromír Chochol and Miroslava Blajerová on archaeological excavation in Březno in 1955.



Text-fig. 2 Jaromír Chochol, Miroslava Blajerová and Hana Hanáková at the bus stop near Březno in 1955.

Modern Period at Oškobrň (Odřepsy catastrophe, Nymburk district) (Blajerová 1974), with traces of a healed intracranial hematoma on the internal surface.

To a certain extent the intentional interventions belong to the group of traumatic conditions. The assortment involves three cases of cranial trepanations; all these have already been treated in literature. Two of them date from the Únětice Culture Period. The skull No. Ao 2497 from Blšany (Louny district) (Pleinerová 1960, Chochol 1967a, Malyková 2002, Likovský and Malyková 2004), the skull No. Ao 9493 from Prague 1-Hradčany has a healed trepanation aperture on the vertex (Likovský 2002, Malyková 2002, Likovský and Malyková 2004). The third skull in the assortment dates from the La Tène Period and is remarkable as the second known case of trepanation from this period in the Czech region (Malyková 2002). The finding No. Ao 1595 comes from Praha 7-Bubeneč (Chochol 1967) (Text-figs 5–7).

Trepanation rondelles are represented by the findings No. Ao 1459 and Ao 5359 (Text-fig. 8).

Among the intentional interventions in skulls in the assortment may also be seen an infant's skull No. 1530 with an intentional deformation, from Lužec nad Vltavou (Mělník district) dating from the Migration Period (Chochol 1969). Another notable finding is the case of intentional shortening of front teeth in maxilla of the skull No. Ao 777 from “Early Medieval Ages” locality Stará Kouřim (Kolín district), but the finding itself dates from the period of Corded Ware Culture (Chochol 1954c).



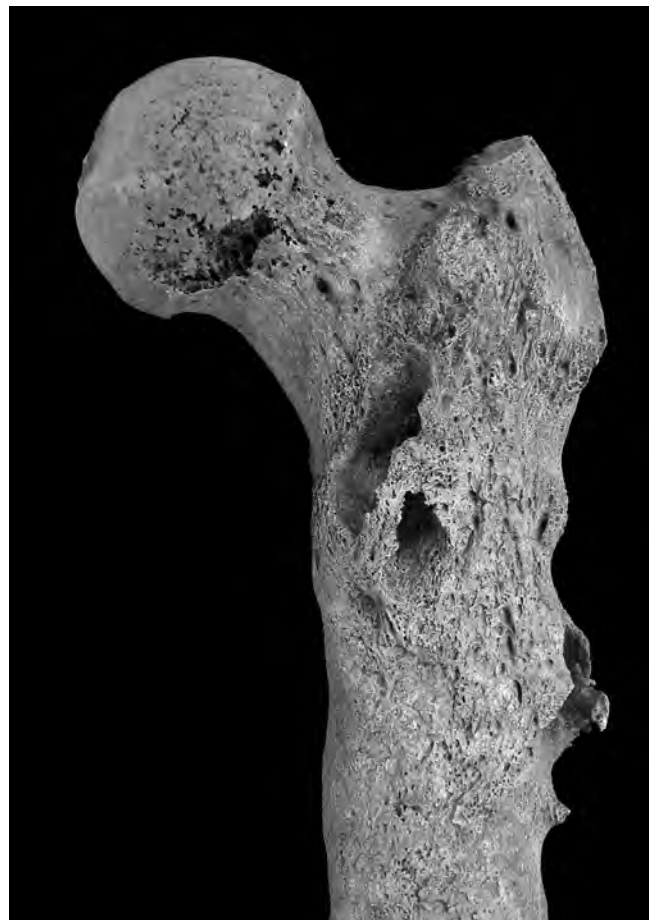Text-fig. 3 Anthropological congress in Mikulov. From the left: Jaromír Chochol, Milan Stloukal and Hana Hanáková, on the right side Miroslava Blajerová.

Due to an inferior state of preservation, the interpretation of finding at the upper limbs of the individual No. Ao 1640b is difficult. This finding comes from Brandýsek (Kladno district) and dates from the 9th to 10th century (Chochol 1957a). Changes observed in all long bones of the upper limbs are probably due to post-inflammatory or maybe even to developmental deformation. The damaged terminals of forearm bones suggest a post-amputation state.

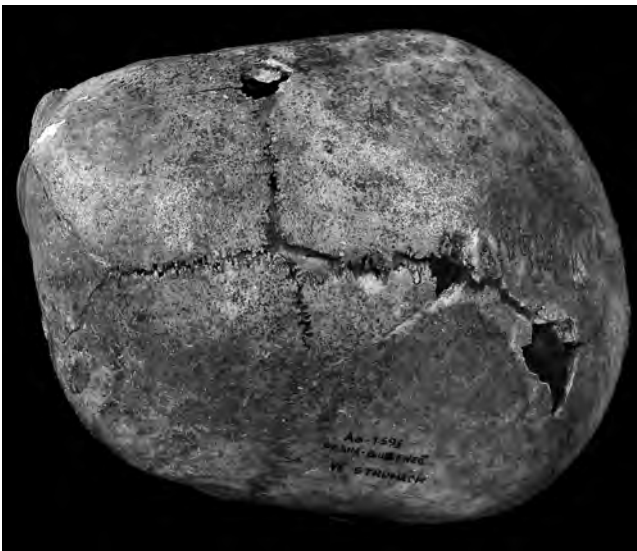
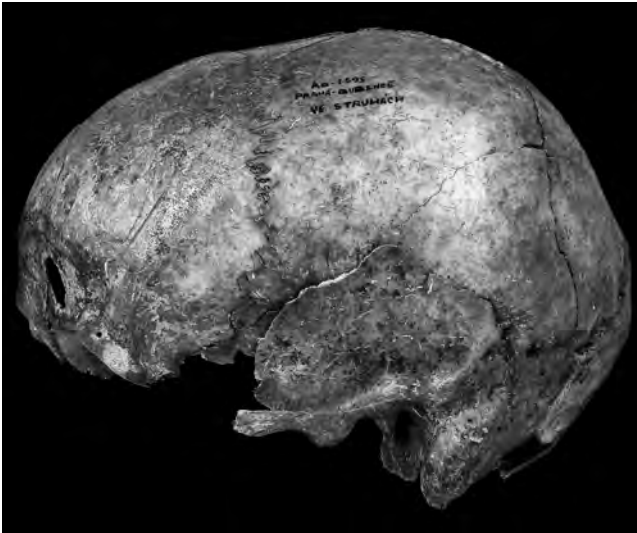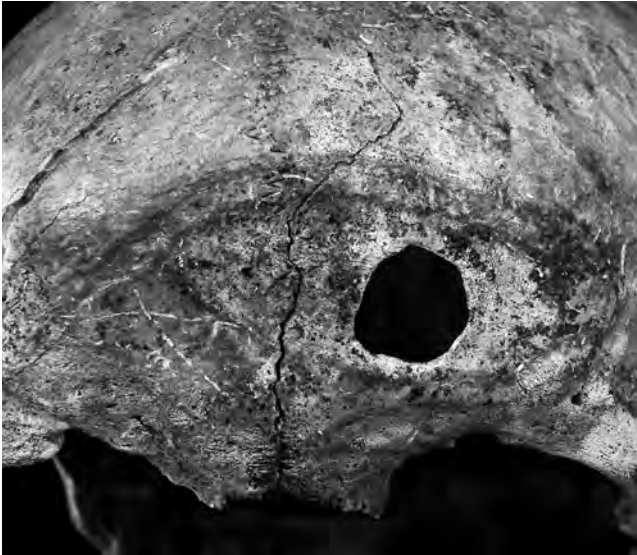Congenital deviations are represented mainly by anomalies of vertebrae or ribs. Interesting are anomalies observed in long bones of extremities involved in the assortment. The most interesting of those anomalies is the finding of Perthes' disease observed on femur and pelvis in No. Ao 1616 which was found in Brandýsek (Kladno district) and dates from the 9th to 10th century (Chochol 1957a). A shortened and delicate right tibia together with the deformed heel bone observed in the No. Ao 375 from Early Medieval Ages which was excavated in Libice nad Cidlinou (Nymburk district) (Hanáková 1969) most likely suggest a congenital deformation of the pes equinovarus type.

A probable developmental affliction is manifested in the skeleton No. Ao 1110 in region of lower limbs whose long bones are shorter and apparently delicate in comparison with the bones of upper limbs. The finding comes from Libice nad Cidlinou (Nymburk district) and dates from the Early Medieval Ages (Hanáková 1969). No signs of injury are apparent on the preserved spine that could be responsible for the paraplegia and thus it is necessary to consider another cause of paralysis, which led to atrophy of the lower limbs.

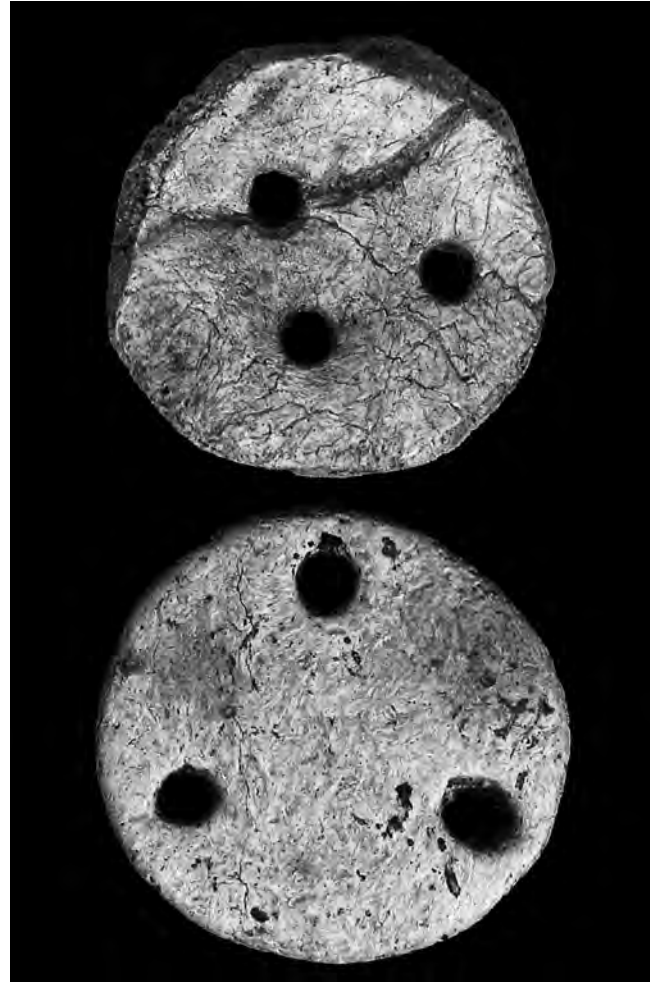
Depressio biparietalis circumscripta is represented by the skull No. Ao 4477 dated from the 8th–9th century, found



Text-fig. 4 One of the illustrative examples of osteomyelitis from assortment of palaeopathological findings: No. Ao 1624 dated to 9th–10th century from Brandýsek.



Text-figs. 5–7. Post-traumatic changes of frontal bone with possible surgical intervention (so-called post-traumatic trepanation) at the skull No. Ao 1595 dated to the La Tène Period from Prague 7-Bubeneč.



Text-fig. 8 Trepanation rondelle from the bones of neurocranium No. Ao 1459 and Ao 5359 dated to La Tène Period and to the Late Hallstatt Period from the localities Prosmuky and Tuchoměřice.

in Nové Zámky, Slovakia (Hanáková and Stloukal 1964, Hanáková and Stloukal 1965).

No malignant tumours were found in the assortment of palaeopathological findings. However, numerous benign osteomas are observed in skull No. Ao 4445, which comes from the 8th–9th century and was found in Nové Zámky, Slovakia (Hanáková and Stloukal 1964, Hanáková and Stloukal 1965).

A curious group of bones is represented by a finding consisting of bones and their fragments with apparent signs of cutting, violent breaking, smashing or burning which date from the Knovíz Culture Period. The bones Nos Ao 930–Ao 937 represent the largest series of this type of findings in the assortment from Břeštiny (Teplice district) (Chochol 1954b). Interpretation of these findings (Chochol 1971, Chochol 1972, Chochol 1974), which are sometimes considered as an evidence of cannibalism, is still a matter for discussion.

Also, there is a group of findings, which do not represent

real pathologies in the assortment of palaeopathological findings. This group consists both of cases of post-mortal damage of bones and of secondary tingeing of the osseous surface. An example of damage of bone by plant roots is represented by the skull No. Ao 1414 found in Mochov (Prague-east district) from the Migration Period (Chochol 1956c, Chochol 1958); damage of bone by rodents may be seen e.g. on the No. Ao 1903 and No. Ao 2565, both from Prague 5-Lahovičky, which date from the Early Medieval Ages (Chochol and Hanáková 1971, Chochol and Hanáková 1973).

A red to violet tingeing attributed to the presence of bacteria *Serratia marcescens* (former *Bacterium prodigiosum*), producing the pigment prodigiosin and commonly associated with the medieval era (Blajerová 2002) is documented by humerus No. Ao 8927 from Prague 2-Vyšehrad (Stránská 1990, Stránská 1991). A green tingeing caused by copper compounds formed through the contact with bronze objects is distinctly apparent on forearms bones No. Ao 6096 from undated material from Prague 1 – Na Františku, and also on frontal and left parietal bones of the skull from Blešno (Hradec Králové district), without No., perhaps from the Early Medieval Ages. Moreover, on the left temple of this skull are observable organic residues, probably hairs. This also belongs to the pseudopathologies.

Another curiosity is represented by bones of upper limb being enveloped by roots of bush or tree, found in Libice nad Cidlinou (Nymburk district), No. Ao 993, dating from the Early Medieval Ages (Hanáková 1969).

The above selection of findings, which are either unique or best represent concrete types of pathological or pseudopathological changes, by far is not exhaustive. All findings in the assortment of palaeopathological findings of the Institute of Archaeology, including the above-mentioned examples, are presented in the Survey of findings.

Fate of the assortment of palaeopathological findings and prospects for their utilization

Depositories of the Department of Anthropology were repeatedly moved – as already mentioned above. The assortment of palaeopathological findings has until now been deposited separately for reason of the primary function: to serve as a comparative and instructional material. Only now, thanks to new depository space of the Museum of Natural sciences in Horní Počernice, is it possible to restore the fund to its original state, where the paleopathological specimens will be reunited with the remainder of their skeletons.

The basic list of whole palaeopathological assortment was made in the year 1999, then the findings were gradually and systematically photographed again, and the description of pathologies and the assigned diagnoses were revised. Also X-ray documentation was supplied for those findings where it was necessary for determination of the diagnoses. Selected findings were consulted with specialists of various clinical departments.

Pathological findings were once separated from skeletons of respective individuals to form the assortment. Due to

this separation it became more difficult in many cases to determine exactly the diagnoses during the revision, and also the side-by-side comparison and evaluation of pathology in connection with the whole finding was not possible. Partly for this reason the individual pathological findings from the palaeopathological assortment will be reunited with the residual parts of their skeletons.

This return of the palaeopathological findings to the remaining material found in particular burial grounds and localities will lead to a higher value of the anthropological collection – even at a cost of dispersing the assortment of palaeopathological findings which then will not exist as such any longer. However, the presented survey with the photographic documentation permits, even after the return of pathological findings to their own skeletal material, treatment of the surveyed pathologies further in a way that hitherto has not been possible. Only now may the collected findings perfectly serve as an educational, comparative and instructional material.

Acknowledgements

The help of RNDr. Miroslava Blajerová, CSc. and of Mrs. Hana Trnková from the Institute of Archaeology of the Czech Academy of Sciences in Prague, who yielded very important information on the origin of the assortment of palaeopathological findings and on particular findings as well, is gratefully acknowledged.

Selected findings were consulted with specialists in clinical departments whose generous help is also gratefully acknowledged. Our thanks are due to rheumatologist MUDr. Jana Barešová, surgeon MUDr. Jiří Poláček, paediatrician and paediatric surgeon MUDr. Petr Jirásek, orthopaedist MUDr. Jan Dobiáš, dental surgeon MUDr. Vladimír Mondschein and radiologists MUDr. Hana Kacerovská, CSc., MUDr. Jana Leskovská and MUDr. Zdeněk Klán.

For making X-ray pictures are our thanks due to Mrs. Alexandra Dekojová and Mrs. Jitka Kulhanová from the Radio-diagnostic department of the hospital in Říčany. For help in the documentation search and in arrangement of the assortment are our thanks due to Mgr. Drahomíra Malyková, Bc. Tereza Davidová and Mr. Jakub Laušman from the Institute of Archaeology of the Czech Academy of Sciences in Prague.

This research was supported by the projects VZ AV ČR AV0Z80020508 and VZ MK00002327201.

Survey of findings

The abbreviations used in the following survey:

Locality – L
Dating – D
Material – M
Pathology – P
Expertise – E
Reference – R

- Ao 6** L.: Libušín, Kladno district
D.: 18th century
M.: cranium
P.: inflammatory perforation of palatum
E.: Blajerová 1955a
R.:
- Ao 121** L.: Libice nad Cidlinou, Nymburk district
D.: Early Medieval Ages
M.: C1, lumbar vertebrae, clavicle left
P.: spina bifida atlantis posterior, degenerative changes, healed clavicle fracture
E.:
R.: Hanáková 1969
- Ao 124** L.: Libice nad Cidlinou, Nymburk district
D.: Early Medieval Ages
M.: C1
P.: ponticulus atlantis posterior
E.:
R.: Hanáková 1969
- Ao 128** L.: Libice nad Cidlinou, Nymburk district
D.: Early Medieval Ages
M.: thoracic vertebrae
P.: deformation of vertebral bodies
E.:
R.: Hanáková 1969
- Ao 138** L.: Libice nad Cidlinou, Nymburk district
D.: Early Medieval Ages
M.: thoracic vertebrae, sternum
P.: compressive fracture of vertebral bodies, perforatio corpus sterni
E.:
R.: Hanáková 1969
- Ao 164** L.: Libice nad Cidlinou, Nymburk district
D.: Early Medieval Ages
M.: femur left, thoracic vertebra
P.: exostosis on diaphysis of middle femur, compressive vertebra fracture
E.:
R.: Hanáková 1969
- Ao 166** L.: Libice nad Cidlinou, Nymburk district
D.: Early Medieval Ages
M.: femur left
P.: osteoma
E.:
R.: Hanáková 1969
- Ao 183** L.: Libice nad Cidlinou, Nymburk district
D.: Early Medieval Ages
M.: bones of hand
P.: ankylosis of phalanges, metacarpals and carpals
E.:
R.: Hanáková 1969
- Ao 186** L.: Libice nad Cidlinou, Nymburk district
D.: Early Medieval Ages
M.: lumbar vertebra
P.: spondylarthritis
- E.:
R.: Hanáková 1969
- Ao 188** L.: Libice nad Cidlinou, Nymburk district
D.: Early Medieval Ages
M.: C1, scapula left, clavicle
P.: osteophyte on superior articular process, opening near coracoid process, clavicle fracture
E.:
R.: Hanáková 1969
- Ao 199** L.: Velim, Kolín district
D.: Bronze Age
M.: cranium
P.: skull surface with postmortal changes probably caused by rootlet erosion
E.:
R.:
- Ao 254** L.: Libice nad Cidlinou, Nymburk district
D.: Early Medieval Ages
M.: bones of right hand, tibia, fibula, cervical and thoracic vertebrae
P.: metacarpophalangeal joint ankylosis, leg fracture, degenerative changes of cervical and thoracic vertebrae
E.:
R.: Hanáková 1969
- Ao 255** L.: Libice nad Cidlinou, Nymburk district
D.: Early Medieval Ages
M.: cervical vertebra, lumbar vertebra
P.: foramen processus transversi partitum, L4 and L5 spondylolysis
E.:
R.: Hanáková 1969
- Ao 263** L.: Libice nad Cidlinou, Nymburk district
D.: Early Medieval Ages
M.: humerus, ulna left
P.: ankylosis of olecranon fossa and olecranon
E.:
R.: Hanáková 1969
- Ao 266** L.: Libice nad Cidlinou, Nymburk district
D.: Early Medieval Ages
M.: thoracic vertebra
P.: spina bifida posterior
E.:
R.: Hanáková 1969
- Ao 280** L.: Klučov, Kolín district
D.: Early Medieval Ages
M.: mandible
P.: coronoid process fracture
E.: Chochol 1953b
R.:
- Ao 368** L.: Praha 1 – Pražský hrad
D.: Middle Ages
M.: femur
P.: healed femur fracture with inflammatory complications

- E.: Blajerová 1979
R.:
- Ao 375** L.: Libice nad Cidlinou, Nymburk district
D.: Early Medieval Ages
M.: tibia right, left, calcaneus right, left
P.: developmental defect of right lower limb bones
E.:
R.: Hanáková 1969
- Ao 451** L.: Libice nad Cidlinou, Nymburk district
D.: Early Medieval Ages
M.: femur right
P.: exostosis on linea aspera
E.:
R.: Hanáková 1969
- Ao 454** L.: Libice nad Cidlinou, Nymburk district
D.: Early Medieval Ages
M.: femur left
P.: traumatic changes of body
E.:
R.: Hanáková 1969
- Ao 524** L.: Libušín, Kladno district
D.: 16th–18th century
M.: foetus
P.: without pathological changes
E.: Blajerová 1955
R.:
- Ao 565** L.: Libice nad Cidlinou, Nymburk district
D.: Early Medieval Ages
M.: lumbar vertebrae
P.: spondylarthritis
E.:
R.: Hanáková 1969
- Ao 567** L.: Libice nad Cidlinou, Nymburk district
D.: Early Medieval Ages
M.: phalanges of thumb right, left, atlas
P.: arthritis of first metatarsophalangeal joint, spina bifida atlantis posterior
E.:
R.: Hanáková 1969
- Ao 572** L.: Libice nad Cidlinou, Nymburk district
D.: Early Medieval Ages
M.: C2 and C3
P.: marginal osteophytes and surface osteophytes on articular facets
E.:
R.: Hanáková 1969
- Ao 574** L.: Libice nad Cidlinou, Nymburk district
D.: Early Medieval Ages
M.: pelvic bone, talus
P.: hip dislocation, degenerative changes of talus with cysts in articular facies
E.:
R.: Hanáková 1969
- Ao 596** L.: Libice nad Cidlinou, Nymburk district
D.: Early Medieval Ages
- M.: atlas
P.: spina bifida anterior
E.:
R.: Hanáková 1969
- Ao 711** L.: Praha 1 – Černínský palác
D.: Early Medieval Ages
M.: humerus right
P.: healed fracture
E.:
R.:
- Ao 772b** L.: Kněžves, Praha-západ district
D.: Bell Beaker Culture
M.: cervical vertebrae
P.: macroporosity and distortion of intervertebral discs of cervical spine (osteochondrosis disci intervertebrales)
E.:
R.:
- Ao 777** L.: Kouřim-Stará Kouřim, Kolín district
D.: Corded Ware Culture
M.: cranium
P.: tooth deformity and mutilation, tooth amputation, inflammatory changes of dental alveolus
E.: Chochol 1954c
R.:
- Ao 892** L.: Praha 1 – Pražský hrad
D.: Middle Ages
M.: L5, S1
P.: sacralization L5 on right-hand side
E.: Blajerová 1979
R.:
- Ao 894** L.: Praha 1 – Pražský hrad
D.: Middle Ages
M.: clavicle right
P.: healed fracture
E.: Blajerová 1979
R.:
- Ao 901** L.: Praha 1 – Pražský hrad
D.: Middle Ages
M.: thoracic vertebrae
P.: Bechterew's disease of thoracic spine
E.: Blajerová 1979
R.:
- Ao 903** L.: Praha 1 – Pražský hrad
D.: Middle Age
M.: tibia
P.: healed fracture of middle tibia
E.: Blajerová 1979
R.:
- Ao 930** L.: Břešťany, Teplice district
D.: Knovíz Culture
M.: cranium
P.: possible secondary artificial intervention
E.: Chochol 1954b
R.:

- Ao 931** L.: Břeštiny, Teplice district
D.: Knovíz Culture
M.: pelvic bone
P.: possible secondary artificial intervention
E.: Chochol 1954b
R.:
- Ao 932** L.: Břeštiny, Teplice district
D.: Knovíz Culture
M.: cranium, femur
P.: possible secondary artificial intervention, artificial intervention on head of femur, cut through body of femur
E.: Chochol 1954b
R.:
- Ao 933** L.: Břeštiny, Teplice district
D.: Knovíz Culture
M.: humerus left
P.: signs of burn on humerus, artificial intervention on body of humerus
E.: Chochol 1954b
R.:
- Ao 934** L.: Břeštiny, Teplice district
D.: Knovíz Culture
M.: parts of skeleton, femur right, fibula right, infant cranium
P.: possible artificial intervention on calcaneus, femurs, signs of burn on tibia, artificial intervention on metatarsals, fibula and fragments of infant skull
E.: Chochol 1954b
R.:
- Ao 935** L.: Břeštiny, Teplice district
D.: Knovíz Culture
M.: calcaneus, metatarsal (infant)
E.: Chochol 1954b
R.:
- Ao 936** L.: Břeštiny, Teplice district
D.: Knovíz Culture
M.: bones of foot (infant)
P.: possible artificial intervention on talus
E.: Chochol 1954b
R.:
- Ao 937** L.: Břeštiny, Teplice district
D.: Knovíz Culture
M.: fibula (infant)
P.: possible artificial intervention
E.: Chochol 1954b
R.:
- Ao 993** L.: Libice nad Cidlinou, Nymburk district
D.: Early Medieval Ages
M.: fragments of humerus right, left
P.: ingrown in wood
E.:
R.: Hanáková 1969
- Ao 997** L.: Libice nad Cidlinou, Nymburk district
D.: Early Medieval Ages
M.: cervical vertebrae
P.: fused vertebrae, compressive fracture
E.:
R.: Hanáková 1969
- Ao 1016** L.: Libice nad Cidlinou, Nymburk district
D.: Early Medieval Ages
M.: femur right
P.: healed dislocated fracture
E.:
R.: Hanáková 1969
- Ao 1025** L.: Libice nad Cidlinou, Nymburk district
D.: Early Medieval Ages
M.: cervical vertebrae
P.: foramen processus transversarium partitum (C6, C7) and exostosis on transverse process (C7)
E.:
R.: Hanáková 1969
- Ao 1076** L.: Libice nad Cidlinou, Nymburk district
D.: Early Medieval Ages
M.: C3 - C4, clavicle, scapula
P.: marginal osteophytes and surface osteophytes on articular facets of cervical spine, healed clavicle fracture, foramen suprascapulare
E.:
R.: Hanáková 1969
- Ao 1089** L.: Libice nad Cidlinou, Nymburk district
D.: Early Medieval Ages
M.: L5
P.: spondylolysis
E.:
R.: Hanáková 1969
- Ao 1099** L.: Libice nad Cidlinou, Nymburk district
D.: Early Medieval Ages
M.: L5
P.: spondylolysis
E.:
R.: Hanáková 1969
- Ao 1102** L.: Libice nad Cidlinou, Nymburk district
D.: Early Medieval Ages
M.: femur right, left, pelvic bone right, left
P.: trochanteritis, inflammatory changes of hip joint
E.:
R.: Hanáková 1969
- Ao 1105** L.: Libice nad Cidlinou, Nymburk district
D.: Early Medieval Ages
M.: tibia
P.: healed fracture of lower tibia
E.:
R.: Hanáková 1969
- Ao 1110** L.: Libice nad Cidlinou, Nymburk district
D.: Early Medieval Ages
M.: femur, tibia right, left

- P.: developmental defect
E.:
R.: Hanáková 1969
- Ao 1111** L.: Libice nad Cidlinou, Nymburk district
D.: Early Medieval Ages
M.: cranium
P.: possible artificial breaking up of neurocranium
E.:
R.: Hanáková 1969
- Ao 1148** L.: Brodce nad Jizerou , Mladá Boleslav district
D.: Únětice Culture
M.: femur, tibia right, left
P.: flat exostosis on femur, possible amputation of leg
E.: Chochol 1954d
R.:
- Ao 1224** L.: Praha 5-Lahovice, Lahovičky
D.: Early Medieval Ages
M.: femur, pelvic bone, thoracic vertebrae
P.: degenerative changes of acetabulum, arthritic changes of head of femur, spondylarthritis
E.: Chochol et Hanáková 1971
R.: Chochol et Hanáková 1973
- Ao 1238** L.: Praha 5-Lahovice, Lahovičky
D.: Early Medieval Ages
M.: lumbar vertebrae
P.: spondylolysis
E.: Chochol et Hanáková 1971
R.: Chochol et Hanáková 1973
- Ao 1243** L.: Praha 5-Lahovice, Lahovičky
D.: Early Medieval Ages
M.: ulna, radius
P.: forearm fracture, healed
E.: Chochol et Hanáková 1971
R.: Chochol et Hanáková 1973
- Ao 1247** L.: Praha 5-Strahov
D.: 14th–16th century
M.: cranium, mandible, tibia right, left
P.: degenerative changes of temporomandibular joint, mandibular torus, osteomyelitis in tibia
E.: Blajerová 1955b
R.:
- Ao 1249** L.: Praha 5-Strahov
D.: 14th–16th century
M.: femur, tibia right, left
P.: arthritis of knee joint
E.: Blajerová 1955b
R.:
- Ao 1251** L.: Praha 5-Strahov
D.: 14th–16th century
M.: mandible
P.: mandibular torus
E.: Blajerová 1955b
R.:
- Ao 1253** L.: Praha 5-Strahov
D.: 14th–16th century
M.: cranium
P.: inflammatory changes of dental alveoli (first and second molars), cutting injury of parietal bone, healed
E.: Blajerová 1955b
R.:
- Ao 1254** L.: Praha 5-Strahov
D.: 14th–16th century
M.: maxilla
P.: maxillar torus
E.: Blajerová 1955b
R.:
- Ao 1280** L.: Libice nad Cidlinou, Nymburk district
D.: Early Medieval Ages
M.: humerus, ulna, radius, scapula left, clavicle left
P.: degenerative changes of shoulder joint, arthritic changes of elbow joint, fracture of acromial end of clavicle, healed
E.:
R.: Hanáková 1969
- Ao 1283** L.: Libice nad Cidlinou, Nymburk district
D.: Early Medieval Ages
M.: thoracic vertebrae
P.: fused thoracic vertebrae
E.:
R.: Hanáková 1969
- Ao 1303** L.: Libice nad Cidlinou, Nymburk district
D.: Early Medieval Ages
M.: L1 - L4
P.: spondylolysis
E.:
R.: Hanáková 1969
- Ao 1304** L.: Libice nad Cidlinou, Nymburk district
D.: Early Medieval Ages
M.: tibia left
P.: tibia fracture
E.:
R.: Hanáková 1969
- Ao 1325** L.: Libice nad Cidlinou, Nymburk district
D.: Early Medieval Ages
M.: cranium, cervical and thoracic vertebrae, tibia left, clavicle left
P.: changes in mandibular fossa, osteoma on head of mandible, fused thoracic vertebrae, marginal osteophytes and surface osteophytes on articular facets of cervical vertebra, clavicle fracture, traumatic changes of proximal articular facet of tibia
E.:
R.: Hanáková 1969
- Ao 1328** L.: Libice nad Cidlinou, Nymburk district
D.: Early Medieval Ages

- M.: cranium
P.: impressive fracture of parietal bone
E.:
R.: Hanáková 1969
- Ao 1335** L.: Libice nad Cidlinou, Nymburk district
D.: Early Medieval Ages
M.: radius right
P.: lower radius fracture, healed
E.:
R.: Hanáková 1969
- Ao 1336** L.: Libice nad Cidlinou, Nymburk district
D.: Early Medieval Ages
M.: lumbar vertebrae
P.: spondylolysis of lumbar vertebrae L4-L5
E.:
R.: Hanáková 1969
- Ao 1411** L.: Mochov, Praha-východ district
D.: Migration Period
M.: maxilla, zygomatic bone
P.: inflammatory changes of maxillar dental alveoli, traumatic changes of zygomatic bone
E.: Chochol 1956c
R.: Chochol 1958
- Ao 1414** L.: Mochov, Praha-východ district
D.: Migration Period
M.: cranium
P.: zygomatic bone fracture, healed, upper medial incisor with caries, inflammatory changes of dental alveolus (upper first molar) and caries (upper second molar)
E.: Chochol 1956c
R.: Chochol 1958
- Ao 1436** L.: Praha 1 – Klášter sv. Anežky
D.: Late Middle Ages
M.: radius, ulna
P.: forearm fracture, with pseudoarthrosis
E.:
R.:
- Ao 1437** L.: Praha 1 – Klášter sv. Anežky
D.: Late Middle Ages
M.: femur left
P.: proximal femur fracture with secondary inflammatory changes, healed
E.:
R.:
- Ao 1440** L.: Praha 1 – Klášter sv. Anežky
D.: Late Middle Ages
M.: cranium, tibia right
P.: cracks on occipital bone, probably caused by postmortal impact, osteomyelitis in tibia
E.:
R.:
- Ao 1456** L.: Pňov, Nymburk district
D.: Early Medieval Ages
M.: humerus left
P.: exostosis on middle humerus
E.: Chochol 1955
R.:
- Ao 1457** L.: Prosmyky, Litoměřice district
D.: Eneolithic
M.: mandible, cranial base, fragments of vertebrae
P.: possible artificial intervention
E.: Chochol 1956b
R.:
- Ao 1459** L.: Prosmyky, Litoměřice district
D.: La Tène Period
M.: cranial bone
P.: rondelle
E.: Chochol 1956b
R.: Chochol 1967a
- Ao 1500** L.: Praha 5-Lahovice, Lahovičky
D.: Early Medieval Ages
M.: femur right, left
P.: markedly anteroposterior deflection of bodies of femurs (rickets)
E.: Chochol et Hanáková 1971
R.: Chochol et Hanáková 1973
- Ao 1505** L.: Praha 5-Lahovice, Lahovičky
D.: Early Medieval Ages
M.: metacarpal, first proximal phalanx
P.: fracture of metacarpal and proximal phalanx, healed
E.: Chochol et Hanáková 1971
R.: Chochol et Hanáková 1973
- Ao 1510** L.: Praha 5-Lahovice, Lahovičky
D.: Early Medieval Ages
M.: cranium (infant)
P.: cribra orbitalia
E.: Chochol et Hanáková 1971
R.: Chochol et Hanáková 1973
- Ao 1512** L.: Praha 5-Lahovice, Lahovičky
D.: Early Medieval Ages
M.: vertebrae, clavicle left
P.: L4 - L5 fused, clavicle fracture, healed
E.: Chochol et Hanáková 1971
R.: Chochol et Hanáková 1973
- Ao 1513** L.: Praha 5-Lahovice, Lahovičky
D.: Early Medieval Ages
M.: femur right, left, pelvic bone upper limb bones
P.: bilateral dysplasia of head of femur – hip dislocation right, ankylosis left
E.: Chochol et Hanáková 1971
R.: Chochol et Hanáková 1973
- Ao 1514** L.: Praha 5-Lahovice, Lahovičky
D.: Early Medieval Ages
M.: humerus, ulna
P.: postmortal changes on body of humerus and ulna (pseudopathology)
E.: Chochol et Hanáková 1971
R.: Chochol et Hanáková 1973

- Ao 1530** L.: Lužec nad Vltavou, Mělník district
D.: Migration Period
M.: cranium (infant)
P.: artificial skull deformation
E.:
R.: Chochol 1969
- Ao 1558** L.: Lužec nad Vltavou, Mělník district
D.: Migration Period
M.: mandible
P.: mandibular fracture, healed with pseudoarthrosis
E.:
R.:
- Ao 1578** L.: Neratovice, Mělník district
D.: Corded Ware Culture
M.: cranium, cervical vertebrae
P.: degenerative changes of cervical vertebrae, parietal foramens
E.:
R.:
- Ao 1594** L.: Březno, Louny district
D.: Únětice Culture
M.: femur
P.: arthritic changes on head of femur
E.:
R.:
- Ao 1595** L.: Praha 7-Bubeneč
D.: La Tène Period
M.: cranium
P.: post-traumatic changes of frontal bone with possible surgical intervention (so-called post-traumatic trepanation)
E.:
R.: Chochol 1967a
- Ao 1607** L.: Kněžves, Praha-západ district
D.: Corded Ware Culture
M.: mandible
P.: intravital loss of molars
E.: Chochol 1956a
R.:
- Ao 1614** L.: Brandýsek, Kladno district
D.: 9th–10th century
M.: ribs, zygomatic bone
P.: congenital ribs ankylosis, traumatic changes of zygomatic bone
E.: Chochol 1957a
R.:
- Ao 1616** L.: Brandýsek, Kladno district
D.: 9th–10th century
M.: femur left, ilium left
P.: Perthes' disease (femur)
E.: Chochol 1957a
R.:
- Ao 1624** L.: Brandýsek, Kladno district
D.: 9th–10th century
M.: patella, femur
- P.: inflammatory changes on articular facets of patella, osteomyelitis in femur
E.: Chochol 1957a
R.:
- Ao 1640a** L.: Brandýsek, Kladno district
D.: 9th–10th century
M.: cranium
P.: cribra orbitalia
E.: Chochol 1957a
R.:
- Ao 1640b** L.: Brandýsek, Kladno district
D.: 9th–10th century
M.: humerus, ulna right, left
P.: elbow deformity (trauma?) and possible bilateral forearm amputation
E.: Chochol 1957a
R.:
- Ao 1646** L.: Brandýsek, Kladno district
D.: 9th–10th century
M.: thoracic vertebrae
P.: fused thoracic vertebrae - incomplete
E.: Chochol 1957a
R.:
- Ao 1649** L.: Brandýsek, Kladno district
D.: 9th–10th century
M.: tibia left
P.: healed fracture
E.: Chochol 1957a
R.:
- Ao 1659** L.: Brandýsek, Kladno district
D.: 9th–10th century
M.: mandible
P.: crowding of lower second incisors
E.: Chochol 1957a
R.:
- Ao 1700** L.: Praha 5-Lahovice, Lahovičky
D.: Early Medieval Ages
M.: femur
P.: osteomyelitis in femur
E.: Chochol et Hanáková 1971
R.: Chochol et Hanáková 1973
- Ao 1718** L.: Praha 5-Lahovice, Lahovičky
D.: Early Medieval Ages
M.: lumbar vertebrae
P.: spondylarthritis
E.: Chochol et Hanáková 1971
R.: Chochol et Hanáková 1973
- Ao 1726a** L.: Praha 5-Lahovice, Lahovičky
D.: Early Medieval Ages
M.: thoracic vertebra
P.: fused thoracic vertebrae
E.: Chochol et Hanáková 1971
R.: Chochol et Hanáková 1973
- Ao 1742** L.: Praha 9-Kbely
D.: Únětice Culture

- M.: humerus, clavicle
P.: traumatic changes of acromial end of clavicle and foramen supratrochleare
E.: Chochol 1957b
R.:
- Ao 1748** L.: Petrohrad, Louny district
D.: Konvív Culture
M.: humerus left
P.: processus supratrochleare
E.: Chochol 1957c
R.:
- Ao 1852** L.: Teplice, Teplice district
D.: 15th–17th century
M.: foetus
P.: without pathological changes
E.: Blajerová 1958
R.: Blajerová 1961
- Ao 1853** L.: Teplice, Teplice district
D.: 15th–17th century
M.: tibia, patella, femur right, metacarpal, thoracic vertebrae
P.: degenerative changes of knee joint, arthritic changes of head of metacarpal, fused thoracic vertebrae
E.: Blajerová 1958
R.: Blajerová 1961
- Ao 1854b** L.: Teplice, Teplice district
D.: half of 13th–half of 15th century
M.: fragment of maxilla
P.: retained canine, bilateral
E.: Blajerová 1958
R.: Blajerová 1961
- Ao 1857** L.: Teplice, Teplice district
D.: Middle Ages
M.: frontal bone
P.: osteoma on internal table of frontal bone
E.: Blajerová 1958
R.: Blajerová 1961
- Ao 1860** L.: Teplice, Teplice district
D.: Middle Ages
M.: ulna, mandible
P.: ulna fracture, healed, mandibular torus
E.: Blajerová 1958
R.: Blajerová 1961
- Ao 1862** L.: Teplice, Teplice district
D.: Middle Ages
M.: lumbar vertebrae, patella
P.: degenerative changes of intervertebral discs of lumbar vertebrae, bilateral arthritis changes on articular facets of patella
E.: Blajerová 1958
R.: Blajerová 1961
- Ao 1903** L.: Praha 5-Lahovice, Lahovičky
D.: Early Medieval Ages
M.: femur
- P.: postmortal changes of bone surface caused by rodents (pseudopathology)
E.: Chochol et Hanáková 1971
R.: Chochol 1973
- Ao 1940** L.: Praha 5-Lahovice, Lahovičky
D.: Early Medieval Ages
M.: vertebra L5
P.: spondylolysis
E.: Chochol et Hanáková 1971
R.: Chochol 1973
- Ao 1942** L.: Teplice, Teplice district
D.: Middle Ages
M.: sternum
P.: fenestratio sterni on body and xiphoid process of sternum
E.: Blajerová 1958
R.: Blajerová 1961
- Ao 1946** L.: Kouřim-Stará Kouřim, Kolín district
D.: Early Medieval Ages
M.: patella
P.: incisura musculi vasti lateralis
E.: Chochol et al. 1959
R.: Chochol et al. 1960
- Ao 1953a** L.: Kouřim-Stará Kouřim, Kolín district
D.: Early Medieval Ages
M.: clavicle right
P.: clavicle fracture, healed
E.: Chochol et al. 1959
R.: Chochol et al. 1960
- Ao 1954** L.: Kouřim-Stará Kouřim, Kolín district
D.: Early Medieval Ages
M.: femur right, clavicle left
P.: arthritic changes on head of femur, clavicle fracture, healed
E.: Chochol et al. 1959
R.: Chochol et al. 1960
- Ao 1958** L.: Kouřim-Stará Kouřim, Kolín district
D.: Early Medieval Ages
M.: metacarpals
P.: traumatic changes of metacarpals
E.: Chochol et al. 1959
R.: Chochol et al. 1960
- Ao 1960** L.: Kouřim-Stará Kouřim, Kolín district
D.: Early Medieval Ages
M.: ribs, sternum, femur left
P.: rib fracture, healed, traumatic changes of sternum, traumatic changes of lateral condyle of femur
E.: Chochol et al. 1959
R.: Chochol et al. 1960
- Ao 1971** L.: Kouřim-Stará Kouřim, Kolín district
D.: Early Medieval Ages
M.: thyroid cartilage, femur, tibia left
P.: ossification of thyroid cartilage, arthritic changes of knee joint

- E.: Chochol et al. 1959
R.: Chochol et al. 1960
- Ao 2114** L.: Sulejovice, Litoměřice district
D.: 10th–11th century
M.: ribs
P.: ribs fracture, healed
E.: Palečková 1958
R.:
- Ao 2118** L.: Sulejovice, Litoměřice district
D.: 10th–11th century
M.: patellae, spine, ribs, clavicle right, left
P.: enthesopathy (patellae, sternal end of clavicle), spondylarthritis of lumbar vertebrae (L1–L4)
E.: Palečková 1958
R.:
- Ao 2324** L.: Praha 5-Lahovice, Lahovičky
D.: Early Medieval Ages
M.: pelvic bone, sacrum
P.: sacro-iliac ankylosis right
E.: Chochol et Hanáková 1971
R.: Chochol 1973
- Ao 2352** L.: Praha 5-Lahovice, Lahovičky
D.: Early Medieval Ages
M.: clavicle
P.: clavicle fracture, healed
E.: Chochol et Hanáková 1971
R.: Chochol 1973
- Ao 2372** L.: Praha 5-Lahovice, Lahovičky
D.: Early Medieval Ages
M.: tibia
P.: soleal fossa
E.: Chochol et Hanáková 1971
R.: Chochol 1973
- Ao 2392** L.: Praha 5-Lahovice, Lahovičky
D.: Early Medieval Ages
M.: fibula
P.: fibrous ossification on lateral malleolus
E.: Chochol et Hanáková 1971
R.: Chochol 1973
- Ao 2418** L.: Praha 5-Lahovice, Lahovičky
D.: Early Medieval Ages
M.: fibula
P.: fibula fracture, healed
E.: Chochol et Hanáková 1971
R.: Chochol 1973
- Ao 2497** L.: Blšany, Louny district
D.: Únětice Culture
M.: cranium, vertebrae
P.: healed trepanation on frontal bone, ponticulus atlantis posterior
E.:
R.: Pleinerová 1960, Chochol 1967, Malyková 2002, Likovský et Malyková 2004
- Ao 2531** L.: Praha 5-Lahovice, Lahovičky
D.: Early Medieval Ages
M.: patella
P.: patella fracture, healed
E.: Chochol et Hanáková 1971
R.: Chochol 1973
- Ao 2544** L.: Praha 5-Lahovice, Lahovičky
D.: Early Medieval Ages
M.: tibia
P.: osteomyelitis in tibia
E.: Chochol et Hanáková 1971
R.: Chochol 1973
- Ao 2565** L.: Praha 5-Lahovice, Lahovičky
D.: Early Medieval Ages
M.: femur, metatarsals
P.: postmortal changes of bone surface caused by rodents (pseudopathology), traumatic degenerative changes of metatarsals
E.: Chochol et Hanáková 1971
R.: Chochol 1973
- Ao 2589** L.: Praha 5-Lahovice, Lahovičky
D.: Early Medieval Ages
M.: ulna left
P.: ulna fracture, healed
E.: Chochol et Hanáková 1971
R.: Chochol 1973
- Ao 2703** L.: Praha 5-Lahovice, Lahovičky
D.: Early Medieval Ages
M.: C1, carpal, metacarpal, phalanges of hand, tibia left, fibula right, left
P.: spina bifida posterior (atlas), lunate asymmetry and traumatic and degenerative changes of phalanx, fibula fracture, healed, traumatic changes of lower fibula - bilateral
E.: Chochol et Hanáková 1971
R.: Chochol 1973
- Ao 2705** L.: Praha 5-Lahovice, Lahovičky
D.: Early Medieval Ages
M.: femur right, tibia right
P.: periostitis on femur and tibia
E.: Chochol et Hanáková 1971
R.: Chochol 1973
- Ao 2714** L.: Praha 5-Lahovice, Lahovičky
D.: Early Medieval Ages
M.: navicular
P.: traumatic changes in middle navicular
E.: Chochol et Hanáková 1971
R.: Chochol 1973
- Ao 2724** L.: Praha 5-Lahovice, Lahovičky
D.: Early Medieval Ages
M.: sacrum, vertebrae
P.: sacralization
E.: Chochol et Hanáková 1971
R.: Chochol 1973

- Ao 2725** L.: Praha 5-Lahovice, Lahovičky
D.: Early Medieval Ages
M.: femur left, tibia right, left
P.: proximal femur fracture, healed, osteomyelitis in tibia
E.: Chochol et Hanáková 1971
R.: Chochol 1973
- Ao 2727** L.: Praha 5-Lahovice, Lahovičky
D.: Early Medieval Ages
M.: humerus, scapula
P.: degenerative changes of shoulder joint
E.: Chochol et Hanáková 1971
R.: Chochol 1973
- Ao 2739** L.: Praha 5-Lahovice, Lahovičky
D.: Early Medieval Ages
M.: humerus right, left
P.: possible hypoplasia
E.: Chochol et Hanáková 1971
R.: Chochol 1973
- Ao 2766** L.: Praha 5-Lahovice, Lahovičky
D.: Early Medieval Ages
M.: radius right, left
P.: postmortal changes of forearm, caused by rodents and rootlet erosion (pseudopathology)
E.: Chochol et Hanáková 1971
R.: Chochol 1973
- Ao 3507** L.: Oškobrh, Nymburk district
D.: 14th century
M.: tibia, fibula, ulna, radius
P.: lower radius fracture, healed, osteomyelitis in leg
E.: Blajerová 1974
R.: Blajerová 1974
- Ao 3762** L.: Žalany, Teplice district
D.: 11th–12th century
M.: femur, tibia right
P.: traumatic knee dislocation with osteomyelitis and degenerative changes, degenerative changes on superior articular surface and deformity of tibia
E.: Hanáková 1963
R.:
- Ao 3766** L.: Žalany, Teplice district
D.: 11th–12th century
M.: maxilla, mandible
P.: inflammatory changes of dental alveoli (molars)
E.: Hanáková 1963
R.:
- Ao 3833** L.: Bílina, Teplice district
D.: 11th–13th century
M.: atlas
P.: spina bifida posterior
E.: Hanáková 1970
R.: Hanáková 1971
- Ao 3942** L.: Radomyšl, Strakonice district
D.: 12th century
M.: cranium
P.: microdontia – premolar (45), asymmetry of parietal bone
E.: Blajerová 1974
R.:
- Ao 4234** L.: Nové Zámky, Nové Zámky district (Slovakia)
D.: 8th–early 9th century
M.: ulna left
P.: traumatic changes of lower ulna
E.: Hanáková et Stloukal 1964
R.: Hanáková et Stloukal 1965
- Ao 4262** L.: Nové Zámky, Nové Zámky district (Slovakia)
D.: 8th–early 9th century
M.: humerus left
P.: humerus fracture, healed
E.: Hanáková et Stloukal 1964
R.: Hanáková et Stloukal 1965
- Ao 4270** L.: Nové Zámky, Nové Zámky district (Slovakia)
D.: 8th–early 9th century
M.: clavicle left, leg left
P.: fracture of acromial end of clavicle, leg fracture, healed
E.: Hanáková et Stloukal 1964
R.: Hanáková et Stloukal 1965
- Ao 4284** L.: Nové Zámky, Nové Zámky district (Slovakia)
D.: 8th–early 9th century
M.: scapula right
P.: degenerative changes
E.: Hanáková et Stloukal 1964
R.: Hanáková et Stloukal 1965
- Ao 4292** L.: Nové Zámky, Nové Zámky district (Slovakia)
D.: 8th–early 9th century
M.: cranium
P.: osteoma on frontal bone, granular foveolae on internal table of neurocranium
E.: Hanáková et Stloukal 1964
R.: Hanáková et Stloukal 1965
- Ao 4304** L.: Nové Zámky, Nové Zámky district (Slovakia)
D.: 8th–early 9th century
M.: humerus, scapula right, left, temporal bone right, left
P.: traumatic shoulder dislocation with secondary distortion changes, asymmetry of mastoid process
E.: Hanáková et Stloukal 1964
R.: Hanáková et Stloukal 1965
- Ao 4309** L.: Nové Zámky, Nové Zámky district (Slovakia)
D.: 8th–early 9th century
M.: humerus right, left
P.: osteomyelitis in humerus
E.: Hanáková et Stloukal 1964
R.: Hanáková et Stloukal 1965

- Ao 4319** L.: Nové Zámky, Nové Zámky district (Slovakia)
D.: 8th–early 9th century
M.: tibia, fibula right, left
P.: tibia and fibula fracture, healed
E.: Hanáková et Stloukal 1964
R.: Hanáková et Stloukal 1965
- Ao 4342** L.: Nové Zámky, Nové Zámky district (Slovakia)
D.: 8th–early 9th century
M.: C2
P.: asymmetry of axis
E.: Hanáková et Stloukal 1964
R.: Hanáková et Stloukal 1965
- Ao 4343** L.: Nové Zámky, Nové Zámky district (Slovakia)
D.: 8th–early 9th century
M.: C1, C2
P.: facies condylaris bipartita and ponticulus atlantis posterior (right)
E.: Hanáková et Stloukal 1964
R.: Hanáková et Stloukal 1965
- Ao 4347** L.: Nové Zámky, Nové Zámky district (Slovakia)
D.: 8th–early 9th century
M.: lower limb phalanx
P.: traumatic changes
E.: Hanáková et Stloukal 1964
R.: Hanáková et Stloukal 1965
- Ao 4360** L.: Nové Zámky, Nové Zámky district (Slovakia)
D.: 8th–early 9th century
M.: thoracic vertebrae
P.: degenerative changes of thoracic and lumbar spine, Schmorl's node in upper vertebral face, sacralization L5
E.: Hanáková et Stloukal 1964
R.: Hanáková et Stloukal 1965
- Ao 4371** L.: Nové Zámky, Nové Zámky district (Slovakia)
D.: 8th–early 9th century
M.: cranium
P.: intravital loss of lower premolar and green tingeing on ramus of mandible (pseudopathology)
E.: Hanáková et Stloukal 1964
R.: Hanáková et Stloukal 1965
- Ao 4399** L.: Nové Zámky, Nové Zámky district (Slovakia)
D.: 8th–early 9th century
M.: tibia right
P.: inflammatory changes of proximal end of tibia
E.: Hanáková et Stloukal 1964
R.: Hanáková et Stloukal 1965
- Ao 4431** L.: Nové Zámky, Nové Zámky district (Slovakia)
D.: 8th–early 9th century
M.: pelvic bone, sacrum
P.: incomplete sacro-iliac ankylosis (right)
E.: Hanáková et Stloukal 1964
R.: Hanáková et Stloukal 1965
- Ao 4445** L.: Nové Zámky, Nové Zámky district (Slovakia)
D.: 8th–early 9th century
M.: cranium
P.: osteomas on left temporal bone and on frontal bone, intravital losses of mandible molars
E.: Hanáková et Stloukal 1964
R.: Hanáková et Stloukal 1965
- Ao 4469** L.: Nové Zámky, Nové Zámky district (Slovakia)
D.: 8th–early 9th century
M.: humerus right
P.: degenerative changes on head
E.: Hanáková et Stloukal 1964
R.: Hanáková et Stloukal 1965
- Ao 4473** L.: Nové Zámky, Nové Zámky district (Slovakia)
D.: 8th–early 9th century
M.: clavicle right, left
P.: traumatic changes of acromial end of clavicle (left) – accessory articular facet (communicated with first rib)
E.: Hanáková et Stloukal 1964
R.: Hanáková et Stloukal 1965
- Ao 4476** L.: Nové Zámky, Nové Zámky district (Slovakia)
D.: 8th–early 9th century
M.: C1
P.: facies condylaris bipartita (right), aplasia of half posterior arch and exostosis on left transversal process
E.: Hanáková et Stloukal 1964
R.: Hanáková et Stloukal 1965
- Ao 4477** L.: Nové Zámky, Nové Zámky district (Slovakia)
D.: 8th–early 9th century
M.: cranium, cervical vertebrae
P.: depressio biparietalis circumscripta, aplasia (right) and hypoplasia (left) of mandibular head and intravital losses, C2-C3 fused, degenerative changes of cervical vertebrae
E.: Hanáková et Stloukal 1964
R.: Hanáková et Stloukal 1965
- Ao 4478** L.: Nové Zámky, Nové Zámky district (Slovakia)
D.: 8th–early 9th century
M.: temporal bone
P.: inflammatory changes of mastoid process and of parietal bones, granular foveolae on internal table of neurocranium
E.: Hanáková et Stloukal 1964
R.: Hanáková et Stloukal 1965
- Ao 4518** L.: Nové Zámky, Nové Zámky district (Slovakia)
D.: 8th–early 9th century
M.: C1
P.: spina bifida posterior
E.: Hanáková et Stloukal 1964
R.: Hanáková et Stloukal 1965
- Ao 4525** L.: Nové Zámky, Nové Zámky district (Slovakia)
D.: 8th–early 9th century
M.: ribs

- P.: rib bifurcation
E.: Hanáková et Stloukal 1964
R.: Hanáková et Stloukal 1965
- Ao 4532** L.: Nové Zámky, Nové Zámky district (Slovakia)
D.: 8th–early 9th century
M.: vertebrae
P.: incompletely fused C2-C3
E.: Hanáková et Stloukal 1964
R.: Hanáková et Stloukal 1965
- Ao 4534** L.: Nové Zámky, Nové Zámky district (Slovakia)
D.: 8th–early 9th century
M.: pelvis
P.: unfused pubic bone with ischeal bone
E.: Hanáková et Stloukal 1964
R.: Hanáková et Stloukal 1965
- Ao 4545** L.: Nové Zámky, Nové Zámky district (Slovakia)
D.: 8th–early 9th century
M.: leg left
P.: traumatic changes of leg with incomplete bridging
E.: Hanáková et Stloukal 1964
R.: Hanáková et Stloukal 1965
- Ao 4573** L.: Nové Zámky, Nové Zámky district (Slovakia)
D.: 8th–early 9th century
M.: tibia right
P.: osteomyelitis in tibia
E.: Hanáková et Stloukal 1964
R.: Hanáková et Stloukal 1965
- Ao 4576** L.: Nové Zámky, Nové Zámky district (Slovakia)
D.: 8th–early 9th century
M.: humerus, ulna, radius right, left
P.: traumatic changes of upper humerus, traumatic changes of distal ulna
E.: Hanáková et Stloukal 1964
R.: Hanáková et Stloukal 1965
- Ao 4587** L.: Nové Zámky, Nové Zámky district (Slovakia)
D.: 8th–early 9th century
M.: metatarsal
P.: traumatic changes of proximal metatarsal
E.: Hanáková et Stloukal 1964
R.: Hanáková et Stloukal 1965
- Ao 4608** L.: Nové Zámky, Nové Zámky district (Slovakia)
D.: 8th–early 9th century
M.: femur, tibia, fibula right, left
P.: dysplasia of lower limb bones (left)
E.: Hanáková et Stloukal 1964
R.: Hanáková et Stloukal 1965
- Ao 4790** L.: Vikletice, Chomutov district
D.: Corded Ware Culture
M.: spine, ribs, sternum
P.: tuberculosis of thoracic spine, rib fracture
E.: Chochol 1968
R.:
- Ao 4959** L.: Bílina, Teplice district
D.: 11th–13th century
M.: tibia, fibula right.
- P.: traumatic changes of articular facet of fibula
E.: Hanáková 1970
R.: Hanáková 1971
- Ao 4980** L.: Bílina, Teplice district
D.: 11th–13th century
M.: femur left
P.: degenerative changes
E.: Hanáková 1970
R.: Hanáková 1971
- Ao 4988** L.: Bílina, Teplice district
D.: 11th–13th century
M.: fourth metatarsal right
P.: metatarsal fracture, healed
E.: Hanáková 1970
R.: Hanáková 1971
- Ao 4994** L.: Bílina, Teplice district
D.: 11th–13th century
M.: ulna, radius left
P.: radius fracture, healed
E.: Hanáková 1970
R.: Hanáková 1971
- Ao 4996** L.: Bílina, Teplice district
D.: 11th–13th century
M.: femur right
P.: lesion near femur epicondyle
E.: Hanáková 1970
R.: Hanáková 1971
- Ao 5010** L.: Bílina, Teplice district
D.: 11th–13th century
M.: lumbar vertebrae
P.: L4-L5 fused
E.: Hanáková 1970
R.: Hanáková 1971
- Ao 5040** L.: Bílina, Teplice district
D.: 11th–13th century
M.: tibia left
P.: inflammatory changes
E.: Hanáková 1970
R.: Hanáková 1971
- Ao 5041** L.: Bílina, Teplice district
D.: 11th–13th century
M.: humerus right, left
P.: medial rotation of distal epiphysis of humerus and bilateral foramen supratrochleare
E.: Hanáková 1970
R.: Hanáková 1971
- Ao 5052** L.: Bílina, Teplice district
D.: 11th–13th century
M.: sacrum
P.: canalis sacralis apertus
E.: Hanáková 1970
R.: Hanáková 1971
- Ao 5060** L.: Bílina, Teplice district
D.: 11th–13th century
M.: atlas, sacrum

- P.: ponticulus atlantis posterior bilateralis,
canalis sacralis apertus
E.: Hanáková 1970
R.: Hanáková 1971
- Ao 5068** L.: Bílina, Teplice district
D.: 11th–13th century
M.: femur right
P.: exostosis in medial part of body
E.: Hanáková 1970
R.: Hanáková 1971
- Ao 5359** L.: Tuhoměřice, Praha-západ
D.: Hallstatt Period
M.: bone from cranium
P.: rondelle
E.:
R.: Chochol 1967a
- Ao 5377** L.: Vikletice, Chomutov district
D.: Corded Ware Culture
M.: fragments of cranium
P.: post-traumatic changes on right mastoid process
E.: Chochol 1968
R.:
- Ao 5432^I** L.: Odřepsy-Oškobrň, Nymburk district
D.: Late Medieval Ages – Modern Period
M.: parietal bone left, femur
P.: healed injury on parietal bone - internal table with possible healed intracranial hematoma, osteomyelitis in proximal femur
E.: Blajerová 1974
R.: Blajerová 1974
- Ao 5432^{II}** L.: Odřepsy-Oškobrň, Nymburk district
D.: Late Medieval Ages – Modern Period
M.: parietal bone left, femur
P.: healed injury on parietal bone, osteomyelitis in proximal femur
E.:
R.: Blajerová 1974
- Ao 5455** L.: Bílina, Teplice district
D.: 11th–13th century
M.: clavicle left
P.: clavicle fracture, healed
E.: Hanáková 1970
R.: Hanáková 1971
- Ao 5463** L.: Bílina, Teplice district
D.: 11th–13th century
M.: humerus, ulna, radius right
P.: humerus fracture and ulna fracture, healed
E.: Hanáková 1970
R.: Hanáková 1971
- Ao 5465a** L.: Bílina, Teplice district
D.: 11th–13th century
M.: atlas
P.: spina bifida anterior
E.: Hanáková 1970
R.: Hanáková 1971
- Ao 5473** L.: Bílina, Teplice district
D.: 11th–13th century
M.: thoracic vertebrae
P.: DISH
E.: Hanáková 1970
R.: Hanáková 1971
- Ao 5474** L.: Bílina, Teplice district
D.: 11th–13th century
M.: femur right
P.: exostosis on dorsal surface of upper femur
E.: Hanáková 1970
R.: Hanáková 1971
- Ao 5475** L.: Bílina, Teplice district
D.: 11th–13th century
M.: lumbar vertebra
P.: spondylolysis
E.: Hanáková 1970
R.: Hanáková 1971
- Ao 5488** L.: Bílina, Teplice district
D.: 11th–13th century
M.: femur right.
P.: traumatic changes of lower femur
E.: Hanáková 1970
R.: Hanáková 1971
- Ao 5490** L.: Bílina, Teplice district
D.: 11th–13th century
M.: metatarsal left
P.: degenerative changes of first metatarsal head
E.: Hanáková 1970
R.: Hanáková 1971
- Ao 6096** L.: Praha 1 – Na Františku
D.: ?
M.: temporal bone, forearm right, left, numerous lower limb bones (4 femurs, 8 tibias)
P.: inflammatory changes near mastoid process, forearm with green color - arising from effects of copper compound, osteomyelitis in lower limb bones, femur fracture, tibia fracture
E.:
R.:
- Ao 6238** L.: Praha 1-Klárov
D.: 13th century
M.: femur right, left
P.: traumatic changes of upper femur (left), probably postmortal changes of lower femur (right)
E.:
R.:
- Ao 6271** L.: Kanín, Nymburk district
D.: Early Medieval Ages
M.: femur right, pelvis, sacrum
P.: pyogenic arthritis with destruction of head
E.: Blajerová 1972
R.:

- Ao 6716** L.: Praha 2-Vyšehrad
D.: 1070–half of 13th century
M.: femur right, left, fibula, patella
P.: arthritis changes of femur, reduced medial articular surface (patella), inflammatory changes of fibula
E.: Stránská 1990
R.: Stránská 1991
- Ao 6730a** L.: Praha 2-Vyšehrad
D.: ?
M.: thoracic vertebrae
P.: DISH
E.: Stránská 1990
R.:
- Ao 6730b** L.: Praha 2-Vyšehrad
D.: ?
M.: sacrum
P.: sacralization of lumbar vertebra
E.: Stránská 1990
R.:
- Ao 7918** L.: Sázava, Kutná Hora district
D.: 11th century
M.: pelvic bones, femur left
P.: degenerative changes of hip joint – acetabulum and detail and head of femur
E.:
R.:
- Ao 7930** L.: Sázava, Kutná Hora district
D.: 11th century
M.: clavicle
P.: degenerative changes of sternal end of clavicle
E.:
R.:
- Ao 7933** L.: Sázava, Kutná Hora district
D.: 11th century
M.: clavicle
P.: degenerative changes of acromioclavicular joint (acromial facet)
E.:
R.:
- Ao 7948** L.: Sázava, Kutná Hora district
D.: 11th century
M.: lumbar vertebra
P.: marginal osteophytes and surface osteophytes on articular facets
E.:
R.:
- Ao 7953** L.: Sázava, Kutná Hora district
D.: 11th century
M.: atlas
P.: aplasia of right transversal process
E.:
R.:
- Ao 7998** L.: Bášt, Praha-východ district
D.: 10th century
M.: humerus right
P.: degenerative changes of shoulder joint
E.: Stránská 1992
R.:
- Ao 8000** L.: Bášt, Praha-východ district
D.: 10th century
M.: cervical vertebrae
P.: marginal osteophytes and surface osteophytes on articular facets of cervical vertebra C2-C5 (left), arthritic changes of dens
E.: Stránská 1992
R.:
- Ao 8003** L.: Bášt, Praha-východ district
D.: 10th century
M.: cervical vertebrae
P.: fused articular facets of C3 and C4
E.: Stránská 1992
R.:
- Ao 8007** L.: Bášt, Praha-východ district
D.: 10th century
M.: ulna left.
P.: ulna fracture, healed
E.: Stránská 1992
R.:
- Ao 8011** L.: Bášt, Praha-východ district
D.: 10th century
M.: humerus left
P.: exostosis on humerus body
E.: Stránská 1992
R.:
- Ao 8026** L.: Bášt, Praha-východ district
D.: 10th century
M.: atlas
P.: ponticulus atlantis lateralis
E.: Stránská 1992
R.:
- Ao 8031** L.: Bášt, Praha-východ district
D.: 10th century
M.: radius left.
P.: distal radius fracture, healed
E.: Stránská 1992
R.:
- Ao 8032** L.: Bášt, Praha-východ district
D.: 10th century
M.: lumbar vertebrae, fibula
P.: spondylarthritis of lumbar vertebrae and detail of inferior articular facet, periostitis on fibula
E.: Stránská 1992
R.:
- Ao 8042** L.: Bášt, Praha-východ district
D.: 10th century
M.: radius left, vertebrae
P.: degenerative changes of lumbar vertebra, enthesopathy (radius)

- E.: Stránská 1992
R.:
- Ao 8072** L.: Bášt, Praha-východ district
D.: 10th century
M.: cervical vertebrae, tibia
P.: degenerative changes of atlanto-occipital joint, fused vertebra C3-C4, degenerative changes of cervical vertebra, degenerative changes of superior articular surface of tibia (knee joint)
E.: Stránská 1992
R.:
- Ao 8099** L.: Bášt, Praha-východ district
D.: 10th century
M.: teeth deciduous
P.: developmental defect – fusion of three teeth – medial and lateral incisors and canine
E.: Stránská 1992
R.:
- Ao 8113** L.: Bášt, Praha-východ district
D.: 10th century
M.: ulna left.
P.: ulna fracture, healed
E.: Stránská 1992
R.:
- Ao 8131** L.: Bášt, Praha-východ district
D.: 10th century
M.: thoracic vertebrae
P.: compressive fracture of thoracic vertebra
E.: Stránská 1992
R.:
- Ao 8138** L.: Bášt, Praha-východ district
D.: 10th century
M.: pelvic bone
P.: sacro-iliac ankylosis, left
E.: Stránská 1992
R.:
- Ao 8927** L.: Praha 2-Vyšehrad
D.: 1070–half of 13th century
M.: humerus, clavicle
P.: purple colored body of humerus (pseudopathology)
E.: Stránská 1990
R.: Stránská 1991
- Ao 8934a** L.: Praha 2-Vyšehrad
D.: 1070–half of 13th century
M.: femur right, left
P.: inflammatory changes on proximal end of femur
E.: Stránská 1990
R.: Stránská 1991
- Ao 8976** L.: Praha 2-Vyšehrad
D.: 1070–half of 13th century
M.: vertebrae Th7-12
P.: tuberculosis of thoracic spine
E.: Stránská 1990
R.:
- Ao 8978b** L.: Praha 2-Vyšehrad
D.: 1070–half of 13th century
M.: femur right, left
P.: flat exostosis on diaphysis
E.: Stránská 1990
R.: Stránská 1991
- Ao 9009a** L.: Praha 2-Vyšehrad
D.: ?
M.: pelvic bone, femur right.
P.: traumatic and inflammatory changes of hip joint
E.: Stránská 1990
R.:
- Ao 9094b** L.: Praha 2-Vyšehrad
D.: ?
M.: scapula right.
P.: osteoperiostitis
E.: Stránská 1990
R.:
- Ao 9095** L.: Praha 2-Vyšehrad
D.: 1070–half of 13th century
M.: femur, humerus, metacarpal, phalanx
P.: degenerative changes on head of femur, exostosis on proximal end of humerus, posttraumatic metacarpophalangeal ankylosis
E.: Stránská 1990
R.: Stránská 1991
- Ao 9103** L.: Praha 2-Vyšehrad
D.: 1070–half of 13th century
M.: tibia
P.: tibia fracture
E.: Stránská 1990
R.: Stránská 1991
- Ao 9103/XI** L.: Praha 2-Vyšehrad
D.: ?
M.: fibula left.
P.: osteomyelitis
E.: Stránská 1990
R.:
- Ao 9103/XV** L.: Praha 2-Vyšehrad
D.: ?
M.: tibia left.
P.: osteomyelitis sclerotisans Garré
E.: Stránská 1990
R.:
- Ao 9327** L.: Sázava, Kutná Hora district
D.: Middle Ages
M.: patella
P.: incisura musculi vasti lateralis
E.: Černý 1993
R.:
- Ao 9329** L.: Sázava, Kutná Hora district
D.: Middle Ages
M.: cranial vault
P.: hyperostosis frontalis interna

- E.: Černý 1993
R.:
- Ao 9331** L.: Sázava, Kutná Hora district
D.: Middle Ages
M.: cervical vertebrae
P.: degenerative changes of intervertebral discs (cervical vertebrae)
E.: Černý 1993
R.:
- Ao 9333** L.: Sázava, Kutná Hora district
D.: Middle Ages
M.: humerus right, left, cervical vertebrae
P.: arthritis of head of humerus, bilateral, degenerative changes of intervertebral discs
E.: Černý 1993
R.:
- Ao 9335** L.: Sázava, Kutná Hora district
D.: Middle Ages
M.: cranial vault, thoracic vertebrae
P.: concavity of skull arising possible from effect of intracranial expansive process and detail of internal table, spondylarthritis of thoracic vertebrae
E.: Černý 1993
R.:
- Ao 9345** L.: Sázava, Kutná Hora district
D.: Middle Ages
M.: clavicle right
P.: costoclavicular fossa
E.: Černý 1993
R.:
- Ao 9364** L.: Sázava, Kutná Hora district
D.: Middle Ages
M.: rib
P.: ossification of costal cartilage
E.: Černý 1993
R.:
- Ao 9365** L.: Sázava, Kutná Hora district
D.: Middle Ages
M.: thoracic vertebrae
P.: Schmorl's node in upper vertebral face
E.: Černý 1993
R.:
- Ao 9369** L.: Sázava, Kutná Hora district
D.: Middle Ages
M.: cervical and thoracic vertebrae, sacrum, patella, clavicle, radius
P.: bridging osteophytes (lumbar vertebrae), Schmorl's node in lower vertebral face (thoracic vertebra), supplementary articular facet on acromial end of clavicle, radius fracture, healed, enthesopathy (patella)
E.:
R.:
- Ao 9370** L.: Sázava, Kutná Hora district
D.: Middle Ages
M.: rib
P.: rib fracture
- E.:
R.:
- Ao 9371** L.: Sázava, Kutná Hora district
D.: Middle Ages
M.: thoracic vertebra
P.: dislocated vertebral arch
E.:
R.:
- Ao 9444** L.: Sázava, Kutná Hora district
D.: Middle Ages
M.: thoracic vertebra
P.: degenerative changes
E.:
R.:
- Ao 9449** L.: Sázava, Kutná Hora district
D.: Middle Ages
M.: thoracic vertebra, lumbar vertebrae, mandible
P.: spondylarthritis, Schmorl's node, dental caries
E.:
R.:
- Ao 9493** L.: Praha 1-Hradčany, Jelení ulice
D.: Únětice Culture
M.: cranium
P.: trepanation on parietal bone, healed
E.: Likovský 2000
R.: Likovský et Malyková 2004
- Ao (not assigned)**
L.: Praha 9-Běchovice
D.: Knovíz Culture
M.: femur and tibia right, left
P.: possible artificial intervention in lower limb bones
E.:
R.:
- Ao (not assigned)**
L.: Blešno, Hradec Králové district
D.: Early Medieval Ages
M.: cranium
P.: green tingeing of neurocranium arising from effects of copper compound, remains of hair (pseudopathology)
E.:
R.:
- Ao (not assigned)**
L.: Praha 5-Lahovice, Lahovičky
D.: Early Medieval Ages
M.: navicular
P.: degenerative changes on articular facets
E.: Chochol et Hanáková 1971
R.: Chochol 1973
- Ao (not assigned)**
L.: Teplice, Teplice district
D.: 15th-17th century
M.: cervical vertebrae
P.: degenerative changes
E.: Blajerová 1958
R.: Blajerová 1961

Index according to the dating

Eneolithic

(Bell Beaker Culture) Ao 772b

(Corded Ware Culture) Ao 777, Ao 1578, Ao 1607, Ao 4790, Ao 5377

(Eneolithic, without determination) Ao 1457

Bronze Age

(Únětice Culture) – Ao 1148, Ao 1594, Ao 2497, Ao 9493

(Knovíz Culture) – Ao 930, Ao 931, Ao 932, Ao 933, Ao 934, Ao 935, Ao 936, Ao 937, Ao 1748, without Ao

(Bronze Age, without determination) – Ao 199

Hallstatt Period

Ao 5359

La Tène Period

Ao 1459, Ao 1595

Migration Period

Ao 1411, Ao 1414, Ao 1530, Ao 1558

Middle Ages

(Early Medieval Ages) – Ao 121, Ao 124, Ao 128, Ao 138,

Ao 164, Ao 166, Ao 183, Ao 186, Ao 188, Ao 254, Ao

255, Ao 263, Ao 266, Ao 280, Ao 375, Ao 451, Ao 454,

Ao 565, Ao 567, Ao 572, Ao 574, Ao 596, Ao 711, Ao

993, Ao 997, Ao 1016, Ao 1025, Ao 1076, Ao 1089, Ao

1099, Ao 1102, Ao 1105, Ao 1110, Ao 1111, Ao 1224,

Ao 1238, Ao 1243, Ao 1280, Ao 1283, Ao 1303, Ao

1304, Ao 1325, Ao 1328, Ao 1335, Ao 1336, Ao 1456,

Ao 1500, Ao 1505, Ao 1510, Ao 1512, Ao 1513, Ao

1514, Ao 1614, Ao 1616, Ao 1624, Ao 1640a, Ao 1640b,

Ao 1646, Ao 1649, Ao 1659, Ao 1700, Ao 1718, Ao

1726a, Ao 1903, Ao 1940, Ao 1946, Ao 1953a, Ao 1954,

Ao 1958, Ao 1960, Ao 1971, Ao 2114, Ao 2118, Ao

2324, Ao 2352, Ao 2372, Ao 2392, Ao 2418, Ao 2531,

Ao 2544, Ao 2565, Ao 2589, Ao 2703, Ao 2705, Ao

2714, Ao 2724, Ao 2725, Ao 2727, Ao 2739, Ao 2766,

Ao 2932, Ao 3762, Ao 3766, Ao 3942, Ao 4234, Ao

4262, Ao 4270, Ao 4284, Ao 4292, Ao 4304, Ao 4309,

Ao 4319, Ao 4342, Ao 4343, Ao 4347, Ao 4360, Ao

4371, Ao 4399, Ao 4431, Ao 4445, Ao 4469, Ao 4473,

Ao 4476, Ao 4477, Ao 4478, Ao 4518, Ao 4525, Ao

4532, Ao 4534, Ao 4545, Ao 4573, Ao 4576, Ao 4587,

Ao 4608, Ao 6271, Ao 7918, Ao 7930, Ao 7933, Ao

7948, Ao 7953, Ao 7998, Ao 8000, Ao 8003, Ao 8007,

Ao 8011, Ao 8026, Ao 8031, Ao 8032, Ao 8042, Ao

8072, Ao 8099, Ao 8113, Ao 8131, Ao 8138, without Ao

(Early / High Medieval Ages) – Ao 3833, Ao 4959, Ao

4980, Ao 4988, Ao 4994, Ao 4996, Ao 5010, Ao 5040,

Ao 5041, Ao 5052, Ao 5060, Ao 5068, Ao 5455, Ao

5463, Ao 5465a, Ao 5473, Ao 5474, Ao 5475, Ao 5488,

Ao 5490, Ao 6716, Ao 8927, Ao 8934a, Ao 8978b, Ao

9095, Ao 9103

(High Medieval Ages) – Ao 1854b, Ao 3507, Ao 6238

(Late Medieval Ages) – Ao 1436, Ao 1437, Ao 1440

(Late Medieval Ages / Modern Period) – Ao 1247, Ao 1249,

Ao 1251, Ao 1253, Ao 1254, Ao 1852, Ao 1853, Ao

3507, Ao 5432^I, Ao 5432^{II}

(Medieval, without determination) – Ao 368, Ao 892, Ao

894, Ao 901, Ao 903, Ao 1857, Ao 1860, Ao 1862, Ao

1942, Ao 9327, Ao 9329, Ao 9331, Ao 9333, Ao 9335,

Ao 9342, Ao 9345, Ao 9364, Ao 9365, Ao 9369, Ao

9370, Ao 9371, Ao 9444, Ao 9449

Modern Period

Ao 6, Ao 524, without Ao

Undeterminable

Ao 6096, Ao 6730a, Ao 6730b, Ao 9009a, Ao 9094b, Ao

91103/XI, Ao 91103/XV

Index according to the localities

Báň – Ao 7998, Ao 8000, Ao 8003, Ao 8007, Ao 8011, Ao

8026, Ao 8031, Ao 8032, Ao 8042, Ao 8072, Ao 8099,

Ao 8113, Ao 8131, Ao 8138

Bílina – Ao 3833, Ao 4959, Ao 4980, Ao 4988, Ao 4994, Ao

4996, Ao 5010, Ao 5040, Ao 5041, Ao 5052, Ao 5060,

Ao 5068, Ao 5455, Ao 5463, Ao 5465a, Ao 5473, Ao

5474, Ao 5475, Ao 5488, Ao 5490

Blešno – without Ao

Blšany – Ao 2497

Brandýsek – Ao 1614, Ao 1616, Ao 1624, Ao 1659, Ao

1640a, Ao 1640b, Ao 1646, Ao 1649,

Brodce nad Jizerou – Ao 1148

Břešťany - Ao 930, Ao 931, Ao 932, Ao 933, Ao 934, Ao

935, Ao 936, Ao 937

Březno – Ao 1594

Kanín – Ao 6271

Klučov – Ao 280

Kněžves – Ao 772b, Ao 1607

Kouřim – Ao 777, Ao 1946, Ao 1953a, Ao 1954, Ao 1958,

Ao 1960, Ao 1971

Libice nad Cidlinou – Ao 121, Ao 124, Ao 128, Ao 138, Ao

164, Ao 166, Ao 183, Ao 186, Ao 188, Ao 254, Ao 255,

Ao 263, Ao 266, Ao 375, Ao 451, Ao 454, Ao 565, Ao

567, Ao 572, Ao 574, Ao 576, Ao 596, Ao 993, Ao 997,

Ao 1016, Ao 1025, Ao 1076, Ao 1089, Ao 1099, Ao 1102,

Ao 1105, Ao 1110, Ao 1111, Ao 1280, Ao 1283, Ao 1303,

Ao 1304, Ao 1325, Ao 1328, Ao 1335, Ao 1336

Libušín – Ao 6, Ao 524

Lužec nad Vltavou – Ao 1530, Ao 1558

Mochov – Ao 1411, Ao 1414

Neratovice – Ao 1578

Nové Zámky – Ao 4234, Ao 4262, Ao 4270, Ao 4284, Ao

4292, Ao 4304, Ao 4309, Ao 4319, Ao 4342, Ao 4343,

Ao 4347, Ao 4360, Ao 4371, Ao 4399, Ao 4431, Ao

4445, Ao 4469, Ao 4473, Ao 4476, Ao 4477, Ao 4478,

Ao 4518, Ao 4525, Ao 4532, Ao 4534, Ao 4545, Ao

4573, Ao 4576, Ao 4587, Ao 4608

Odrěpsy – Ao 3507, Ao 5432

Petrohrad – Ao 1748

Pňov – Ao 1456

Praha 1 [Anežský klášter (Convent of St. Agnes)] – Ao 1436, Ao 1437, Ao 1440.
 Praha 1 [Pražský Hrad (Prague Castle)] Ao 368, Ao 892, Ao 894, Ao 901, Ao 903
 Praha 1 (Klárov) – Ao 6238
 Praha 1 (Jelení ulice) – Ao 9493
 Praha 1 (Černínský palác) – Ao 711
 Praha 1 (Na Františku) – Ao 6096
 Praha 2-Vyšehrad – Ao 6716, Ao 6730a, Ao 6730b, Ao 8927, Ao 8934a, Ao 8976, Ao 8978b, Ao 9009a, Ao 9094b, Ao 9095, Ao 9103, Ao 9103/XI, Ao 9103/XV
 Praha 5-Lahovičky – Ao 1224, Ao 1238, Ao 1243, Ao 1500, Ao 1505, Ao 1510, Ao 1512, Ao 1513, Ao 1514, Ao 1700, Ao 1718, Ao 1726a, Ao 1903, Ao 1940, Ao 2324, Ao 2352, Ao 2372, Ao 2392, Ao 2418, Ao 2531, Ao 2544, Ao 2565, Ao 2589, Ao 2703, Ao 2705, Ao 2714, Ao 2724, Ao 2725, Ao 2727, Ao 2739, Ao 2766
 Praha 5-Strahov – Ao 1247, Ao 1249, Ao 1251, Ao 1253, Ao 1254
 Praha 7-Bubeneč – Ao 1595
 Praha 9-Běchovice – without Ao
 Praha 9-Kbely – Ao 1742
 Prosimky – Ao 1457, Ao 1459
 Radomyšl – Ao 3942
 Sázava – Ao 7918, Ao 7930, Ao 7933, Ao 7948, Ao 7953, Ao 9327, Ao 9329, Ao 9331, Ao 9333, Ao 9335, Ao 9342, Ao 9345, Ao 9364, Ao 9365, Ao 9369, Ao 9370, Ao 9371, Ao 9444, Ao 9449
 Stehelčevy – without Ao
 Sulejovice – Ao 2114, Ao 2118
 Teplice – Ao 1852, Ao 1853, Ao 1854b, Ao 1857, Ao 1860, Ao 1862, Ao 1942
 Tuhoměřice – Ao 5359
 Velim – Ao 199
 Vikletice – Ao 4790, Ao 5377
 Žalany – Ao 3762, Ao 3766

Index according to the pathological conditions

Skull

Developmental anomalies, asymmetry, depressio biparietalis circumscripta, hyperostosis frontalis interna – Ao 3942, Ao 4304, Ao 4477, Ao 9329, Ao 9335
 Cribra orbitalia – Ao 1510, Ao 1640a
 Degenerative changes of temporomandibular joint – Ao 1247, Ao 1325
 Traumatic changes
 Calvarium – Ao 1253, Ao 1328, Ao 5377, Ao 5432^I, Ao 5432^{II}
 Splanchnocranium – Ao 1411, Ao 1414, Ao 1614
 Mandible – Ao 280, Ao 1558
 Trepanation – Ao 1595, Ao 2497, Ao 9493
 Rondelle – Ao 1459, Ao 5359

Artificial skull deformation – Ao 1530
 Inflammatory changes – Ao 6, Ao 4478, Ao 6096
 Osteoma – Ao 1325, Ao 1857, Ao 4292, Ao 4445
 Maxillar or mandibular torus – Ao 1247, Ao 1251, Ao 1254, Ao 1860
 Developmental anomalies of teeth – Ao 1659, Ao 1854b, Ao 3942, Ao 8099
 Dental caries, intravital loos, inflammatory changes of alveoli – Ao 777, Ao 1253, Ao 1411, Ao 1414, Ao 1607, Ao 3766, Ao 4371, Ao 4445, Ao 4477, Ao 9449
 Teeth mutilation – Ao 777

Vertebral column and sacrum

Anatomical variants, congenital and developmental anomalies
 Vertebrae – Ao 121, Ao 124, Ao 128, Ao 188, Ao 255, Ao 266, Ao 567, Ao 596, Ao 1025, Ao 1089, Ao 1099, Ao 1238, Ao 1283, Ao 1303, Ao 1325, Ao 1336, Ao 1646, Ao 1726a, Ao 1853, Ao 1940, Ao 2497, Ao 2703, Ao 3833, Ao 4342, Ao 4343, Ao 4476, Ao 4518, Ao 4532, Ao 5060, Ao 5465a, Ao 5475, Ao 7953, Ao 8026
 Sacrum – Ao 892, Ao 2724, Ao 4360, Ao 5052, Ao 5060, Ao 6730b
 Degenerative changes
 Vertebrae – Ao 121, Ao 186, Ao 254, Ao 565, Ao 572, Ao 772b, Ao 1076, Ao 1224, Ao 1325, Ao 1512, Ao 1578, Ao 1718, Ao 1862, Ao 2118, Ao 4360, Ao 4477, Ao 5010, Ao 7948, Ao 8000, Ao 8003, Ao 8032, Ao 8042, Ao 8072, Ao 8131, Ao 9331, Ao 9333, Ao 9335, Ao 9365, Ao 9369, Ao 9371, Ao 9474, Ao 9449, not assigned finding
 Sacro-iliac ankylosis – Ao 2324, Ao 4431, Ao 8138
 Compressive fracture of vertebral body – Ao 138, Ao 164, Ao 997, Ao 8131, Ao 9444
 Tuberculosis – Ao 4790, Ao 8976
 DISH (Diffuse idiopathic skeletal hyperostosis, Forestier disease) – Ao 5473, Ao 6730a
 Bechterew's disease – Ao 901

Thorax

Congenital and developmental anomalies
 Ribs – Ao 1614, Ao 4525
 Sternum – Ao 138, Ao 1942
 Traumatic changes
 Ribs – Ao 1960, Ao 2114, Ao 4790, Ao 9370
 Sternum – Ao 1960
 Ossifications
 Ribs – Ao 9345

Clavicle, scapula and bones of upper extremity

Anatomical variants, congenital and developmental anomalies – Ao 188, Ao 1076, Ao 1748, Ao 2739, Ao 5041, Ao 9345
 Degenerative changes
 Shoulder joint – Ao 1280, Ao 2727, Ao 4284, Ao 4304, Ao 4469, Ao 7933, Ao 7998, Ao 9333
 Elbow joint – Ao 263, Ao 1280, Ao 1640b
 Phalanges, metacarpals and carpals joints – Ao 183, Ao 254

Exostosis

Humerus – Ao 1456, Ao 8011, Ao 9095

Traumatic changes

Clavicle – Ao 121, Ao 188, Ao 894, Ao 1076, Ao 1280, Ao 1325, Ao 1512, Ao 1742, Ao 1953a, Ao 1954, Ao 2352, Ao 4270, Ao 4473, Ao 5455

Humerus – Ao 711, Ao 4262, Ao 4576, Ao 5463

Radius and ulna – Ao 263, Ao 1243, Ao 1335, Ao 1436, Ao 1860, Ao 2589, Ao 3507, Ao 4234, Ao 4576, Ao 4994, Ao 5463, Ao 8007, Ao 8031, Ao 8113, Ao 9369

Phalanges, metacarpals and carpals – Ao 1505, Ao 1958, Ao 2703, Ao 9095

Amputation – Ao 1640b

Inflammatory changes

Scapula – Ao 9094b

Humerus – Ao 4309

Pelvic bone and bones of lower extremity

Anatomical variants, congenital and developmental anomalies – Ao 375, Ao 574, Ao 1110, Ao 1500, Ao 1513, Ao 1616, Ao 1946, Ao 2372, Ao 4534, Ao 4608, Ao 9327

Degenerative changes

Hip joint – Ao 1224, Ao 1594, Ao 1954, Ao 4980, Ao 6716, Ao 7918, Ao 9095

Knee joint – Ao 1249, Ao 1853, Ao 1862, Ao 1971, Ao 3762, Ao 8072

Phalangeal, metatarsal and tarsal joints – Ao 567, Ao 574, Ao 1853, Ao 2565, Ao 5490

Osteoma, exostosis

Femur – Ao 164, Ao 166, Ao 451, Ao 1148, Ao 5068, Ao 5474, Ao 8978b

Traumatic changes

Femur – Ao 368, Ao 454, Ao 1016, Ao 1437, Ao 1960, Ao 2725, Ao 3762, Ao 4996, Ao 5488, Ao 6096, Ao 6238

Patella – Ao 2531

Tibia and fibula – Ao 254, Ao 903, Ao 1105, Ao 1304, Ao 1325, Ao 1649, Ao 2392, Ao 2418, Ao 2703, Ao 3762, Ao 4270, Ao 4319, Ao 4545, Ao 4959, Ao 6096, Ao 8032, Ao 9103

Phalanges, metatarsals and tarsals – Ao 2714, Ao 4347, Ao 4587, Ao 4988

Amputation – Ao 1148

Inflammatory changes

Hip joint – Ao 1102, Ao 9009a

Femur – Ao 1102, Ao 1624, Ao 1700, Ao 2705, Ao 3762, Ao 5432^I, Ao 5432^{II}, Ao 6096, Ao 6271, Ao 8934a, Ao 9009

Tibia and fibula – Ao 1247, Ao 1440, Ao 2544, Ao 2705, Ao 2725, Ao 3507, Ao 3762, Ao 4319, Ao 4399, Ao 4573, Ao 5040, Ao 6096, Ao 6716, Ao 8032, Ao 9103/XI, Ao 9103/XV

Possible postmortal intentional interventions

Ao 930, Ao 931, Ao 932, Ao 933, Ao 934, Ao 935, Ao 936, Ao 937, Ao 1111, Ao 1440, Ao 1457, not assigned finding

Pseudopathologies

Damage of bone surface – Ao 199, Ao 1514, Ao 1903, Ao 2565, Ao 2766

Miscellaneous conditions – Ao 993, Ao 4371, Ao 6096, Ao 8927, not assigned finding

Other findings

Foetus – Ao 524, Ao 1852

Ossification of thyreoid cartilage – Ao 1971

References

Blajerová, M. (1955a): Libušínské kostrové nálezy ze XVI.–XVIII. století. – Anthropological expertise, Archive of Inst. of Archaeology CAS.

Blajerová, M. (1955b): Nálezy lidských kostrových pozůstatků na Strahově. – Anthropological expertise, Archive of Inst. of Archaeology CAS.

Blajerová, M. (1958): Lidské kostrové nálezy z Teplic (výzkum 1957). – Anthropological expertise, Archive of Inst. of Archaeology CAS.

Blajerová, M. (1961): Tělesné vlastnosti středověkého obyvatelstva z Teplic (pohřebiště při románské basilice). – Památky archeologické, 52: 652–660.

Blajerová, M. (1972): Slovanské pohřebiště druhé poloviny 9. až 10. století z Kanína, okres Nymburk (Anthropologické zpracování). – Anthropological expertise, Archive of Inst. of Archaeology CAS.

Blajerová, M. (1974a): Anthropologická charakteristika kosterních pozůstatků ze středověkého pohřebiště na Oškobrhu. – Památky archeologické, 65: 185–217.

Blajerová, M. (1974b): Anthropologická charakteristika obyvatelů Radomyšle ze hřbitova kolem kostela sv. Martina. – Anthropological expertise, Archive of Inst. of Archaeology CAS.

Blajerová, M. (1974c): Kosterné pozůstatky ze středověkého pohřebiště na Oškobrhu. – Anthropological expertise, Archive of Inst. of Archaeology CAS.

Blajerová, M. (1979): Kostrové pozůstatky ze slovanského pohřebiště u Královské jízdárny na Pražském Hradě. – Anthropological expertise, Archive of Inst. of Archaeology CAS.

Blajerová, M. (2002): Středověké kostrové pozůstatky ze Starého Mýta. – Anthropological expertise, Archive of Inst. of Archaeology CAS.

Blajerová, M., Šaldová, V. (1986): Životní jubileum Jaromíra Chochoła. – Archeologické rozhledy, 38: 292–298.

Brothwell, D. R. (1968): The skeletal biology of earlier human populations. – Pergamon Press, Oxford.

Černý, V. (1993): Anthropologický materiál ze Sázavského kláštera (kaple p. Marie). – Anthropological expertise, Archive of Inst. of Archaeology CAS.

Ekenman, I., Eriksson, S. A. V., Lindgren, J. U. (1995): Bone density in medieval skeletons. – Calcified Tissue International, 56: 355–358.

Guiyoule, A. E., Grimont, F., Iteman, I., Grimont, P. A. D.,

- Lefevre, M., Carniel, E. (1994): Plague pandemics investigated by ribotyping of *Yersinia pestis* strains. – *Journal of Clinical Mikrobiology*, 32: 634–641.
- Hanáková, H. (1963): Antropologický rozbor slovanských kostrových pozůstatků z Žalan (u Teplíc). – *Památky archeologické*, 54: 308–314.
- Hanáková, H. (1969): Eine anthropologische Analyse der slawischen Skelette aus dem Burgwall von Libice nad Cidlinou. – *Anthropologie*, 7 (2): 3–30.
- Hanáková, H. (1970): Slovanské pohřebiště v Bílině. – *Anthropological expertise, Archive of Inst. of Archaeology CAS*.
- Hanáková, H. (1971): Die slawische Begräbnisstätte aus Bílina. – *Anthropologische Analyse, Anthropologie*, 9 (2): 111–128.
- Hanáková H., Stloukal M. (1964): Anthropologie Slovanů z pohřebiště v Nových Zámkách. – *Anthropological expertise, Archive of Inst. of Archaeology CAS*.
- Hanáková H., Stloukal M. (1966): Anthropologie der Slawen aus dem Gräberfeld in Nové Zámky. – *Slovenská archeológia*, 14 (1): 167–204.
- Hanáková, H., Vyhnánek, L. (1981): Paläopathologische Befunde aus dem Gebiet der Tschechoslowakei. – *Acta Musei Nationalis Pragae, Series B, Historia Naturálie*, 37 B (1): 1–76.
- Chochol, J. (1953a): Anthropologie únětické skupiny z Března u Loun. – *Anthropological expertise, Archive of Inst. of Archaeology CAS*.
- Chochol, J. (1953b): Zlomek dolní čelisti z Klučova (období hradištní). – *Anthropological expertise, Archive of Inst. of Archaeology CAS*.
- Chochol, J. (1954a) : Lidská čelist ze slovanského hradiště v Klučově. – *Archeologické rozhledy*, 6 (2): 194–196.
- Chochol, J. (1954b): Lidské kosti z knovízských jam č. IX.–XVII. z Břešťan, o. Teplice. – *Anthropological expertise, Archive of Inst. of Archaeology CAS*.
- Chochol, J. (1954c): Neolitické kostry ze Staré Kouřimě. – *Anthropological expertise, Archive of Inst. of Archaeology CAS*.
- Chochol, J. (1954d): Přehled výsledků předběžného antropologického zpracování kostrových hrobů z Brodců nad Jizerou. (Hroby č. 5, 8, 9, 10, 12, 15, 16, 18, 19, 20, 21, 22). – *Anthropological expertise, Archive of Inst. of Archaeology CAS*.
- Chochol, J. (1955): Zpráva o předběžné prohlídce kostrového materiálu z mladohradištního pohřebiště u Pňova, o. Poděbrady. – *Anthropological expertise, Archive of Inst. of Archaeology CAS*.
- Chochol, J. (1956a): Anthropologický posudek o kostrových pozůstatcích ze šňůrového hrobu v Kněževsi. – *Anthropological expertise, Archive of Inst. of Archaeology CAS*.
- Chochol, J. (1956b): Anthropologický posudek o eneolitické kostře z Prosmyk. – *Anthropological expertise, Archive of Inst. of Archaeology CAS*.
- Chochol, J. (1956c): Kostrové pozůstatky z doby stěhování národů odkryté při výzkumu v Mochově. – *Anthropological expertise, Archive of Inst. of Archaeology CAS*.
- Chochol, J. (1957a): Antropologický rozbor slovanské populace z Brandýsku. – *Anthropological expertise, Archive of Inst. of Archaeology CAS*.
- Chochol, J. (1957b): Kostrové pozůstatky z porušeného únětického pohřebiště ve Kbelích. – *Anthropological expertise, Archive of Inst. of Archaeology CAS*.
- Chochol, J. (1957c): Zbytky knovízské kostry z Petrohradu. – *Anthropological expertise, Archive of Inst. of Archaeology CAS*.
- Chochol, J. (1958): Kostrové pozůstatky z doby stěhování národů odkryté při výzkumu v Mochově. – *Památky archeologické*, 49: 472–477.
- Chochol, J. (1967a): K problematice prehistorických a protohistorických lebečních trepanací. Antropologické zhodnocení některých nálezů z Čech. – *Anthropologie*, 5 (3): 3–34.
- Chochol, J. (1967b): Kostrové pozůstatky „vampýrů“ z Radomyšle. – *Anthropological expertise, Archive of Inst. of Archaeology CAS*.
- Chochol, J. (1968): Antropologický rozbor pozůstatků lidu s kulturou šňůrové keramiky ve Vikleticích. – *Anthropological expertise, Archive of Inst. of Archaeology CAS*.
- Chochol, J. (1969): Ein künstlich deformierter Kinderschädel aus der Zeit der Völkerwanderung (Fundort Lužec nad Vltavou, Bez. Mělník, Böhmen). – *Anthropologie*, 7: 11–17.
- Chochol, J. (1970): Die anthropologische Analyse der auf dem schnurkeramischen Gräberfelde von Vikletice geborgenen Menschenreste. – In: Buchvaldek, M., Koutecký, D. (eds.), *Vikletice. Ein schnurkeramisches Gräberfeld, Praehistoria*, 3: 257–283.
- Chochol, J. (1971): Antropologická problematika kostrových hrobů knovízské kultury v Čechách (s komentářem J. Hraly). – *Památky archeologické*, 62: 324–363.
- Chochol, J. (1972): Anthropologische problematik der böhmischen Knovízer Kultur. – *Homo* 22: 12–19.
- Chochol, J. (1973): Anthropologie staroslovanské skupiny z Lahovic u Prahy. – *Památky archeologické*, 64: 393–462.
- Chochol, J. (1974): Kostrové materiály knovízské kultury ze severozápadních Čech. – *Crania bohemia* 3. Archeologický ústav Československé akademie věd, Praha.
- Chochol, J., Blajerová, M., Palečková, H. (1958): Starounětická kostra ze Žabovřesk o. Lovosice. – *Anthropological expertise, Archive of Inst. of Archaeology CAS*.
- Chochol, J., Blajerová, M., Palečková, H. (1959): Kostrové pozůstatky slovanského obyvatelstva na Staré Kouřimi. První část – knížecí pohřebiště „U Libuše“. – *Anthropological expertise, Archive of Inst. of Archaeology CAS*.
- Chochol, J., Blajerová, M., Palečková, H. (1960): Kostrové pozůstatky slovanského obyvatelstva na Staré Kouřimi. – *Památky archeologické*, 51: 294–331.
- Chochol, J., Hanáková H. (1971): Anthropologie staroslovanské skupiny z Lahovic u Prahy. – *Anthropological expertise, Archive of Inst. of Archaeology CAS*.
- Lees, B. Molleson, T., Stevenson, J. C., Arnett, T. R. (1993):

- Differences in proximal femur bone density over two centuries. – *Lancet* 341: 673–675.
- Likovský, J. (2000): Lebky z únětického dvojhrabu v Praze 1 – Jelení ulici. – *Anthropological expertise, Archive of Inst. of Archaeology CAS*.
- Likovský, J., Drda, P. (2003): Epidurální krvácení na lebce z brány A oppida Závist. – *Archeologické rozhledy*, 55, 2: 285–296.
- Likovský, J., Malyková, D. (2004): Trepanace lebky z únětického dvojhrabu v Praze – Jelení ulici a její srovnání s nálezy trepanací podobného datování z území Čech. – *Archeologické rozhledy*, 56, 4: 841–849.
- Malyková, D. (2002): Trepanace lebky v archeologických nálezech z území Čech. – *Archeologie ve středních Čechách*, 6: 293–314.
- Manialawi, M., Meligy, R., Bucaille, M. (1978): Endoscopic examination of Egyptian mummies. – *Endoscopy*, 10: 191–194.
- Mays, S. A. (1999): Osteoporosis in earlier human population. – *Journal Clinical Densitometry*, 2: 71–78.
- Mays, S. A., Lees, B., Stevenson, J. C. (1998): Age dependent bone loss in the femur in medieval population. – *International Journal of Osteoarchaeology*, 8: 97–106.
- Němečková, A., Strouhal, E. (2003): Zhoubné nádory dávných lidí z pohledu biomedicíny. – In: Sládek et al. (eds.), *Evoluce člověka a antropologie recentních populací*. pp 87–94, Aleš Čeněk, Dobrá Voda u Pelhřimova.
- Palečková, H. (1957): Anthropologický dodatek o kostrových pozůstatcích z Turska. – *Anthropological expertise, Archive of Inst. of Archaeology CAS*.
- Palečková, H. (1958): Anthropologický rozbor slovanského pohřebiště v Sulejovicích, o. Lovosice. – *Anthropological expertise, Archive of Inst. of Archaeology CAS*.
- Pleinerová, I. (1960): Únětické pohřebiště a osada v Blšanech u Loun. – *Památky archeologické*, 51: 488–524.
- Poulsen, L. W., Qvesel, D., Brixen, K., Vesterby, A., Boldsen, L. (2001): Low bone mineral density in femoral neck of medieval women: a result of multiparity? – *Bone*, 28: 454–458.
- Stránská, P. (1990): Středo-až novověké kostrové pozůstatky z lokality Vyšehrad. – *Anthropological expertise, Archive of Inst. of Archaeology CAS*.
- Stránská, P. (1991): Antropologická charakteristika středověkých až novověkých pozůstatků z Vyšehradu. – *Archaeologica Pragensia*, 11: 321–354.
- Stránská, P. (1992): Antropologický kostrový materiál z Báště. – *Anthropological expertise, Archive of Inst. of Archaeology CAS*.
- Strouhal, E. (1998): Z historie paleopatologie u nás a ve světě. – *Dějiny věd a techniky*, 31: 81–98.
- Strouhal, E., Horáčková, L., Likovský, J., Vargová, L., Daneš, J. (2002): Traces of leprosy from Czech Kingdom. – In: Roberts, Ch. (ed.), *The past and present of leprosy: archaeological, historical, palaeopathological and clinical approaches*. pp. 223–232, Archaeopress, Oxford.
- Šefčáková, A., Strouhal, E., Němečková, A., Thurzo, M., Stašíšková-Štukovská, D. (2001): Case of metastatic carcinoma from end of the 8th–early 9th century Slovakia. – *American Journal of Physical Anthropology*, 116: 216–229.
- Velemínský, P., Likovský, J., Trefný, P., Dobisíková, M., Velemínská, J., Poláček, L., Hanáková, H. (2005): Anthropologische Analyse des Großmährischen Gräberfeldes Kostelisko im Suburbium des Burgwall von Mikulčice. – *Studien zum Burgwall von Mikulčice, Band IV, Spisy AÚ AV ČR, Brno: 1–95*.
- Vyhnaněk L. (1999): Nárys kosterní paleopatologie se zaměřením na radiodiagnostiku. In: Stloukal, M. et al. *Antropologie. Příručka pro studium kostry*, pp. 386–432, Národní muzeum, Praha.

Explanation to the plates

All photos by J. Likovský.

PLATE 1

- 1.–3. Ao 6 – skull and detail of inflammatory perforation of palatum.
4. Ao 121 – spina bifida posterior (atlas).
- 5.–7. Ao 121 – degenerative changes of lumbar vertebrae.
8. Ao 121 – clavicle fracture.
9. Ao 124 – ponticulus atlantis posterior.
10. Ao 128 – deformation of vertebral bodies (thoracic spine).

PLATE 2

1. Ao 138 – perforatio corpus sterni.
2. Ao 138 – compressive fracture of thoracic vertebra.
3. Ao 164 – exostosis on diaphysis of femur.
- 4., 5. Ao 164 – compressive fracture of thoracic vertebra.
- 6., 7. Ao 166 – osteoma on diaphysis of femur.
- 8., 9. Ao 183 – ankylosis of phalanges, metacarpals and carpals.
10. Ao 254 – bilateral ankylosis of first metacarpophalangeal joint.

PLATE 3

1. Ao 186 – spondyloarthritis of lumbar vertebra.
2. Ao 188 – osteophytes on superior articular process of atlas.
3. Ao 188 – clavicular fracture.
4. Ao 188 – foramen suprascapulare.
5. Ao 199 – pseudopathological changes on skull arising from effects of environment.
- 6., 7. Ao 254 – degenerative changes of second cervical vertebrae and vertebrae C7 and Th1.
8. Ao 254 – degenerative changes of cervical and thoracic vertebrae.
9. Ao 254 – fracture crural bones.

PLATE 4

1. Ao 255 – foramen processus transversarii partitum.
2. Ao 255 – spondylolysis of lumbar vertebrae L4-L5.
3. Ao 263 – ankylosis of humerus (olecranon fossa) and ulna (olecranon).
4. Ao 266 – spina bifida posterior (thoracic vertebra).
5. Ao 280 – coronoid process fracture.
6. Ao 368 – femur fracture with inflammatory complications, healed.
- 7.–9. Ao 375 – developmental defect of right lower limb bones.
10. Ao 451 – exostosis on linea aspera (femur).
11. Ao 454 – traumatic changes of lower femur.
12. Ao 565 – spondylarthritis of lumbar vertebra.

PLATE 5

1. Ao 565 – spondylarthritis of lumbar spine.
2. Ao 567 – spina bifida posterior (atlas).
3. Ao 567 – arthritic changes of first metatarsophalangeal joint.
4. Ao 572 – marginal osteophytes and surface osteophytes on articular facets of C2 and C3.
5. Ao 574 – hip dislocation.
- 6., 7. Ao 574 – degenerative changes of talus with cysts in articular facies.
8. Ao 596 – spina bifida anterior (atlas).
9. Ao 772b – macroporosity and distortion of intervertebral discs of cervical spine (osteochondrosis disci intervertebrales).
- 10., 11. Ao 777 – frontal tooth mutilation with palatal side detail.
12. Ao 777 – inflammatory changes of dental alveolus (lower second molar).
13. Ao 892 – right unilateral sacralization of lumbar vertebra L5.
14. Ao 894 – clavicle fracture, healed.

PLATE 6

- 1., 2. Ao 901 – Bechterew's disease of thoracic spine.
3. Ao 903 – tibia fracture, healed.
- 4., 5. Ao 930 – fragments of skull vault – possible secondary artificial intervention.
6. Ao 931 – fragments of pelvic bones – possible secondary artificial intervention.
- 7.–10. Ao 932 – fragments of skull vault – secondary artificial intervention.
11. Ao 932 – detail of parietal bone border.
12. Ao 932 – cut through body of femur.
- 13., 14. Ao 932 – artificial intervention on femoral head.

PLATE 7

1. Ao 933 – signs of burn on humerus.
2. Ao 933 – artificial intervention on body of humerus.
3. Ao 934 – possible artificial intervention on calcaneus.

4. Ao 934 – possible artificial intervention on femur.
5. Ao 934 – signs of burn on tibia.
- 6., 7. Ao 934 – artificial intervention on femur.
8. Ao 934 – artificial intervention on metatarsals.
9. Ao 934 – artificial intervention on fibula.
10. Ao 934 – possible artificial intervention on fragments of infant skull.
11. Ao 935 – possible artificial intervention on calcaneus.
12. Ao 936 – possible artificial intervention on infant talus.
13. Ao 936 – possible artificial intervention on distal epiphysis of infant fibula.
14. Ao 937 – possible artificial intervention on infant fibula.
15. Ao 997 – fused of vertebrae.

PLATE 8

1. Ao 1025 – foramen processus transversarii partitum (C6, C7) and exostosis on transverse process (C7).
2. Ao 1076 – marginal osteophytes and surface osteophytes on articular facets of cervical spine.
3. Ao 1076 – foramen suprascapulare.
4. Ao 1089 – spondylolysis of lumbar vertebra (L5).
5. Ao 1099 – spondylolysis of lumbar vertebra (L5).
6. Ao 1102 – inflammatory changes of hip joint.
7. Ao 1102 – inflammatory changes of trochanters of femur.
8. Ao 1105 – tibia fracture, healed.
9. Ao 1110 – developmental defect of lower limb bones.
10. Ao 1111 – possible artificial breaking up of neurocranium.
- 11., 12. Ao 1148 – flat exostosis (femurs).
13. Ao 1148 – possible amputation of lower limb (tibia, fibula).

PLATE 9

1. Ao 1224 – degenerative changes of acetabulum.
2. Ao 1224 – arthritic changes of femoral head.
3. Ao 1238 – spondylolysis.
4. Ao 1243 – forearm fracture, healed.
- 5., 6. Ao 1247 – osteomyelitis of tibia.
7. Ao 1247 – degenerative changes of temporomandibular joint.
- 8.–10. Ao 1249 – arthritis of knee joint – femur (8, 9) and tibia (10).
11. Ao 1251 – mandibular torus.
12. Ao 1253 – cutting injury of parietal bone, healed.
- 13., 14. Ao 1254 – maxillar torus.
- 15., 16. Ao 1280 – degenerative changes of shoulder joint – glenoid cavity (15), head of humerus (16).
17. Ao 1280 – arthritic changes of elbow joint.
18. Ao 1280 – fracture of acromial end of clavicle, healed.

PLATE 10

- 1., 2. Ao 1283 – fused thoracic vertebrae.
3. Ao 1304 – tibia fracture.
4. Ao 1325 – changes in mandibular fossa.
5. Ao 1325 – osteoma on head of mandibule.
- 6., 7. Ao 1325 – fused thoracic vertebrae.
8. Ao 1325 – marginal osteophytes and surface osteophytes on articular facets of cervical vertebra.
9. Ao 1325 – clavicle fracture.
10. Ao 1325 – traumatic changes of proximal articular facet of tibia.
11. Ao 1328 – impressive fracture of parietal bone.
12. Ao 1335 – lower radius fracture, healed.
13. Ao 1336 – spondylolysis of lumbar vertebrae L4–L5.
14. Ao 1411 – inflammatory changes of maxillar dental alveoli.
15. Ao 1411 – traumatic changes of zygomatic bone.
16. Ao 1414 – zygomatic bone fracture, healed.

PLATE 11

1. Ao 1414 – upper medial incisor with caries.
2. Ao 1414 – inflammatory changes of dental alveolus (upper first molar) and caries (upper second molar).
- 3., 4. Ao 1436 – forearm fracture, with pseudoarthrosis.
- 5., 6. Ao 1437 – proximal femur fracture with secondary inflammatory changes healed.
7. Ao 1440 – cracks on occipital bone, probably caused by postmortal impact
8. Ao 1456 – exostosis on middle humerus.
9. Ao 1500 – markedly anteroposterioric deflection of femoral bodies (rachitis?).
10. Ao 1505 – fracture of metacarpal and proximal phalanx, healed.
11. Ao 1510 – cribra orbitalia.
12. Ao 1512 – clavicle fracture, healed.
13. Ao 1512 – L4–L5 fused.
- 14., 15. Ao 1513 – bilateral dysplasia of head of femur – hip dislocation right, ankylosis left.

PLATE 12

- 1., 2. Ao 1514 – postmortal changes on body of humerus and ulna (pseudopathology).
- 3.–5. Ao 1530 – artificial skull deformation.
- 6., 7. Ao 1558 – mandibular fracture, healed with pseudoarthrosis.
8. Ao 1578 – parietal foramens.
9. Ao 1578 – degenerative changes of cervical vertebrae.
10. Ao 1594 – arthritic changes on head of femur.
11. Ao 1607 – intravital loss of molars.
12. Ao 1614 – congenital ribs ankylosis.
13. Ao 1614 – traumatic changes of zygomatic bone.
14. Ao 1616 – Perthes' disease (femur).

PLATE 13

1. Ao 1624 – inflammatory changes on articular facets of patella.

2. Ao 1640a – cribra orbitalia.
- 3., 4. Ao 1640b – elbow deformity (trauma?) and possible bilateral forearm amputation.
5. Ao 1646 – fused thoracic vertebrae – incomplete.
6. Ao 1649 – tibia fracture, healed.
7. Ao 1659 – crowding of lower second incisors.
8. Ao 1700 – osteomyelitis in femur.
9. Ao 1718 – spondylarthritis of lumbar vertebra.
- 10., 11. Ao 1726a – fused thoracic vertebrae.
12. Ao 1742 – traumatic changes of acromial end of clavicle and foramen supratrochleare.
13. Ao 1748 – fused thoracic vertebrae.
14. Ao 1853 – fused thoracic vertebrae.
15. Ao 1853 – arthritic changes of head of metacarpal.
- 16., 17. Ao 1853 – degenerative changes of knee joint – femur (16) and patella (17).
18. Ao 1854b – retained canine, bilateral (maxilla).

PLATE 14

1. Ao 1857 – osteoma on internal table of frontal bone.
2. Ao 1860 – mandibular torus.
3. Ao 1860 – ulna fracture, healed.
4. Ao 1862 – degenerative changes of intervertebral discs of lumbar vertebrae.
5. Ao 1862 – bilateral arthritis changes on articular facets of patella.
6. Ao 1903 – postmortal changes on body of femur (pseudopathology).
7. Ao 1940 – spondylolysis of lumbar vertebra.
8. Ao 1942 – fenestration of sternum.
9. Ao 1946 – incisura musculi vasti lateralis (patella).
10. Ao 1953a – clavicle fracture, healed.
11. Ao 1954 – clavicle fracture, healed.
12. Ao 1954 – arthritic changes on head of femur.
13. Ao 1958 – traumatic changes of metacarpals.
14. Ao 1960 – traumatic changes of sternum.
15. Ao 1960 – rib fracture, healed.
16. Ao 1960 – traumatic changes of lateral condyle of femur.
- 17., 18. Ao 1971 – arthritic changes of knee joint.

PLATE 15

1. Ao 1971 – ossification of thyroid cartilage.
- 2., 3. Ao 2114 – rib fracture, healed.
4. Ao 2118 – enthesopathy (sternal end of clavicle).
5. Ao 2118 – spondylarthritis of lumbar vertebrae (L1–L4).
6. Ao 2324 – sacro-iliac ankylosis.
7. Ao 2352 – clavicle fracture, healed.
8. Ao 2372 – fossa solei (femur).
9. Ao 2392 – fibrous ossification on lateral malleolus.
10. Ao 2418 – fibula fracture, healed.
11. Ao 2497 – ponticulus atlantis posterior.
12. Ao 2531 – patella fracture, healed.
13. Ao 2544 – osteomyelitis in tibia.
14. Ao 2565 – postmortal changes of bone surface, caused by rodents (pseudopathology).

15. Ao 2565 – traumatic degenerative changes of metatarsals.
16. Ao 2589 – ulna fracture, healed.
17. Ao 2703 – spina bifida posterior (atlas).
- 18., 19. Ao 2703 – lunate asymmetry and traumatic and degenerative changes of phalanx.
20. Ao 2703 – fibula fracture, healed.
21. Ao 2703 – traumatic changes of lower fibula – bilateral.

PLATE 16

- 1.-4. Ao 2497 – healed trepanation (frontal bone and detail of defect).

PLATE 17

- 1., 2. Ao 2705 – periostitis on femur (1) and on tibia (2).
3. Ao 2714 – traumatic changes in middle navicular
- 4., 5. Ao 2724 – sacralization – dorsal (4) and ventral (5) view.
6. Ao 2725 – proximal femur fracture, healed.
7. Ao 2725 – osteomyelitis of tibia.
- 8., 9. Ao 2727 – degenerative changes of shoulder joint – scapula (8) and humerus (9).
10. Ao 2766 – postmortal changes of forearm (pseudopathology).
11. Ao 3507 – lower radius fracture, healed.
- 12., 13. Ao 3507 – osteomyelitis of lower limb bones.
- 14., 15. Ao 3762 – traumatic knee dislocation with osteomyelitis and degenerative changes.

PLATE 18

- 1., 2. Ao 3762 – degenerative changes on superior articular surface and deformity of tibia.
3. Ao 3766 – inflammatory changes of dental alveoli (molars).
4. Ao 3833 – spina bifida posterior (atlas).
5. Ao 3942 – microdontia – premolar.
6. Ao 4234 – traumatic changes of ulna.
7. Ao 4262 – humerus fracture, healed.
8. Ao 4272 – fracture of acromial end of clavicle.
- 9., 10. Ao 4272 – leg fracture, healed.
11. Ao 4292 – osteoma on frontal bone.
12. Ao 4292 – granular foveolae on internal table of neurocranium.
13. Ao 4304 – asymmetry of mastoid process.
- 14., 15. Ao 4304 – traumatic shoulder dislocation with secondary distortion changes – humerus (14) and scapula (15).
- 16., 17. Ao 4309 – osteomyelitis in humerus – lateral (16) and medial (17) side.
- 18., 19. Ao 4342 – asymmetry of axis.

PLATE 19

- 1., 2. Ao 4343 – facies condylaris bipartita and ponticulus atlantis posterior (right).
- 3., 4. Ao 4347 – traumatic changes of lower limb phalanx.

5. Ao 4360 – degenerative changes and Schmorl's node of thoracic and lumbar spine.
6. Ao 4360 – Schmorl's node in upper vertebral face (thoracic vertebra).
7. Ao 4371 – intravital loss of lower premolar and green tingeing on ramus of mandible (pseudopathology).
8. Ao 4399 – inflammatory changes of proximal end of tibia.
- 9., 10. Ao 4431 – incomplete sacro-iliac ankylosis (right).
- 11., 12. Ao 4445 – osteoma on frontal bone – left.
13. Ao 4445 – osteomas on left temporal bone.
14. Ao 4469 – degenerative changes on head of humerus.
15. Ao 4473 – traumatic changes of acromial end of clavicle (left) – accessory. articular facet (communicated with first rib).
16. Ao 4476 – facies condylaris bipartita (right), aplasia of half posterior arch and exostosis on left transversal process (atlas).
- 17.–20. Ao 4477 – depressio biparietalis circumscripta.
21. Ao 4477 – aplasia (right) and hypoplasia (left) of mandibular head and intravital losses.
22. Ao 4477 – C2-C3 fused.
23. Ao 4477 – degenerative changes of cervical vertebrae.

PLATE 20

1. Ao 4478 – inflammatory changes of mastoid process.
2. Ao 4478 – inflammatory changes of parietal bones.
3. Ao 4478 – granular foveolae on internal table of neurocranium.
4. Ao 4518 – spina bifida posterior (atlas).
5. Ao 4525 – rib bifurcation.
6. Ao 4532 – incompletely fused C2-C3.
7. Ao 4545 – traumatic changes of leg with incomplete bridging.
8. Ao 4573 – osteomyelitis in tibia.
9. Ao 4576 – traumatic changes of upper humerus.
10. Ao 4576 – traumatic changes of distal ulna.
11. Ao 4587 – traumatic changes of proximal metatarsal.
- 12.–14. Ao 4608 – dysplasia of lower limb bones (left) – femur (12,13) and leg (14).
15. Ao 4959 – traumatic changes of articular facet of fibula.
16. Ao 4988 – metatarsal fracture, healed.
17. Ao 4994 – radius fracture, healed.
18. Ao 4996 – lesion near femur epicondyle.
19. Ao 5010 – L4–L5 fused.
20. Ao 5040 – inflammatory changes of femur.
21. Ao 5041 – medial rotation of distal epiphysis of humerus and bilateral foramen supratrochleare.

PLATE 21

- 1.-3. Ao 4790 – tuberculosis of thoracic spine.
4. Ao 5052 – canalis sacralis apertus.
5. Ao 5060 – ponticulus atlantis posterior bilateralis.
6. Ao 5060 – canalis sacralis apertus.
7. Ao 5068 – exostosis on femoral diaphysis.
8. Ao 5432 – healed injury on parietal bone – internal table with possible healed intracranial hematoma.

PLATE 22

- 1., 2. Ao 5432 – healed injury on parietal bone – internal table (1) and external table (2).
- 3., 4. Ao 5432 – healed cutting injury on parietal bone (left) – external table (3) and internal table (4).
5. Ao 5432 – osteomyelitis of proximal femur.
6. Ao 5432 – osteomyelitis (femur).
7. Ao 5455 – clavicle fracture, healed.
- 8., 9. Ao 5463 – humerus fracture (10) and ulna fracture (11), healed.
10. Ao 5465a – spina bifida anterior.
11. Ao 5473 – DISH (thoracic spine).
12. Ao 5473 – exostosis on dorsal surface of upper femur.
13. Ao 5475 – spondylolysis of thoracic vertebra.
14. Ao 5488 – traumatic changes of lower femur.
15. Ao 5490 – degenerative changes of first metatarsal head.
16. Ao 6096 – femur fracture, healed.
17. Ao 6096 – osteomyelitis of femur.
18. Ao 6096 – osteomyelitis of lower limb bones.
19. Ao 6096 – osteomyelitis of femur.

PLATE 23

1. Ao 6096 – osteomyelitis in tibia.
2. Ao 6096 – osteomyelitis in femoral diaphysis.
3. Ao 6096 – inflammatory changes near mastoid process.
4. Ao 6096 – forearm with green tingeing – arising from effects of copper compound.
5. Ao 6238 – traumatic changes of upper femur.
- 6., 7. Ao 6238 – probably postmortal changes of lower femur.
- 8., 9. Ao 6271 – sacrum asymmetry.
- 10., 11. Ao 6716 – reduced medial articular surface (patella).
12. Ao 6716 – inflammatory changes of fibula.
13. Ao 6730a – DISH (thoracic spine).
14. Ao 6730b – sacralization of lumbar vertebra.
- 15.-17. Ao 7918 – degenerative changes of hip joint – acetabulum and detail (15,16) and head of femur (17).

PLATE 24

1. Ao 7930 – marginal osteophytes and surface osteophytes on articular facets of cervical vertebra C6-C7.
2. Ao 7930 – degenerative changes of sternal end of clavicle.

- 3., 4. Ao 7933 – degenerative changes of acromioclavicular joint (acromial facet).
5. Ao 7948 – marginal osteophytes and surface osteophytes on articular facets of lumbar vertebra.
6. Ao 7953 – aplasia of right transversal process (atlas).
7. Ao 7998 – degenerative changes of shoulder joint.
8. Ao 8000 – marginal osteophytes and surface osteophytes on articular facets of cervical vertebra C2-C5 (left).
9. Ao 8000 – arthritic changes of dens.
10. Ao 8007 – marginal osteophytes and surface osteophytes on articular facets of cervical vertebra (right).
11. Ao 8007 – ulna fracture, healed.
12. Ao 8011 – exostosis on humerus body.
13. Ao 8031 – distal radius fracture, healed.
- 14., 15. Ao 8032 – spondylarthritis of lumbar vertebrae and detail of inferior articular facet.
16. Ao 8032 – periostitis on fibula.

PLATE 25

1. Ao 8042 – degenerative changes of lumbar vertebra.
2. Ao 8042 – enthesopathy (radius).
3. Ao 8064 – periostitis of femur.
4. Ao 8072 – degenerative changes of atlanto-occipital joint.
5. Ao 8072 – fused vertebra C3-C4.
6. Ao 8072 – degenerative changes of cervical vertebra.
7. Ao 8072 – degenerative changes of superior articular surface of tibia (knee joint).
- 8., 9. Ao 8099 – developmental defect – fusion of three teeth – medial and lateral incisors and canine.
10. Ao 8113 – ulna fracture, healed.
- 11., 12. Ao 8131 – compressive fracture of thoracic vertebra.
13. Ao 8138 – sacro-iliac ankylosis.
14. Ao 8927 – purple tingeing of humerus body (pseudopathology).
- 15., 16. Ao 8934 a – inflammatory changes on proximal end of femur.
17. Ao 8976 – tuberculosis of thoracic spine.
18. Ao 9009a – traumatic changes of hip joint.
19. Ao 9095 – exostosis on proximal end of humerus.
20. Ao 9095 – posttraumatic metacarpophalangeal ankylosis.
21. Ao 9103 – tibia fracture, dislocated.
22. Ao 9103-XV – sclerosing osteomyelitis of Garré in tibia.
- 23., 24. Ao 9284 – degenerative changes of cervical spine – C5-C6 (23) and C6-C7 (24).

PLATE 26

- 1.-4. Ao 9284 – degenerative changes of hip joint – head of femur (1,3), acetabulum (2,4).

- 5., 6. Ao 9327 – incisura musculi vasti lateralis.
7. Ao 9329 – hyperostosis frontalis interna.
8. Ao 9331 – degenerative changes of intervertebral discs (cervical vertebrae).
9. Ao 9333 – degenerative changes of intervertebral discs (cervical vertebrae).
- 10., 11. Ao 9333 – arthritis of head of humerus, bilateral.
12. Ao 9345 – costoclavicular fossa.
13. Ao 9335 – spondylarthritis of thoracic vertebrae.
- 14.–16. Ao 9335 – concavity of skull arising possible from effect of intracranial expansive process and detail of internal table.
5. Ao 9369 – radius fracture, healed.
6. Ao 9369 – Schmorl's node in lower vertebral face (thoracic vertebra).
7. Ao 9369 – enthesopathy (patella).
8. Ao 9369 – bridging osteophytes (thoracic vertebrae).
9. Ao 9370 – rib fracture.
10. Ao 9371 – dislocated vertebral arch (thoracic vertebra).
11. Ao 9444 – degenerative changes of thoracic vertebral body.
- 12., 13. Ao 9493 – trepanation, healed.
14. Ao 9730 – spondylarthritis, marginal osteophytes and surface osteophytes on articular facets and macroporosity and distortion of intervertebral discs (cervical vertebrae).
- 15.–17. not assigned – possible artificial intervention in lower limb bones.
- 18., 19. not assigned – green body neurocranium arising from effects of copper compound, residues of hair.

PLATE 27

1. Ao 9364 – ossification of costal cartilage.
2. Ao 9365 – Schmorl's node in upper vertebral face (thoracic vertebra).
3. Ao 9369 – bridging osteophytes (lumbar vertebrae).
4. Ao 9369 – supplementary articular facet on acromial end of clavicle.

Cover: Skeleton No. Ao 7439 with the probable tuberculous inflammatory changes of carpal bones in the exposition of the Museum of the Capital City of Prague comes from Prague 8-Čimice and is dated to the Únětice Culture; primarily was examined by J. Chochol in 1977.

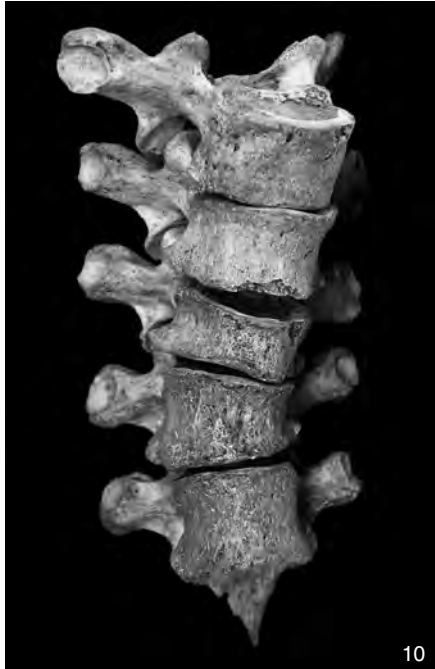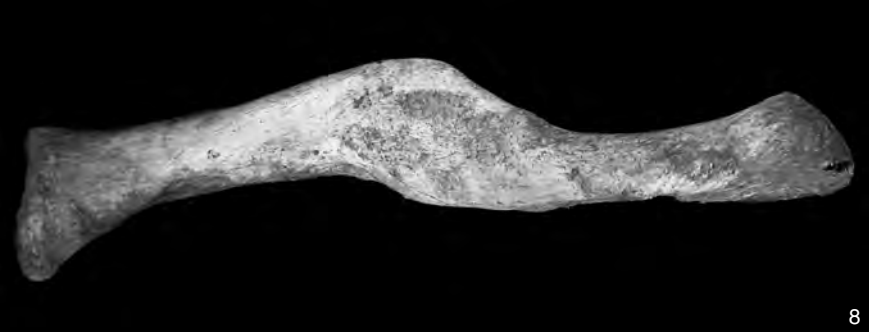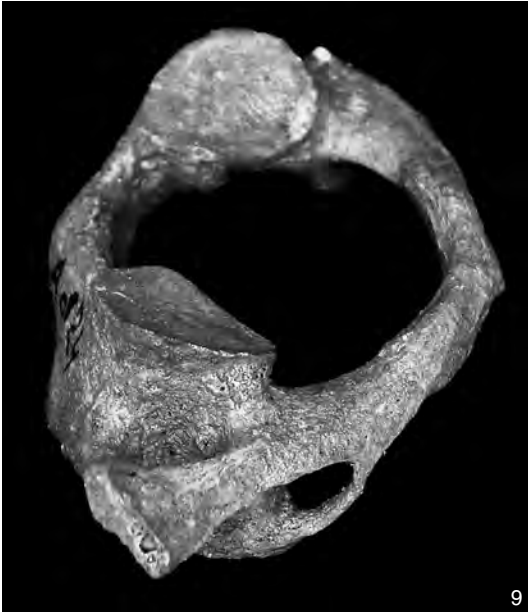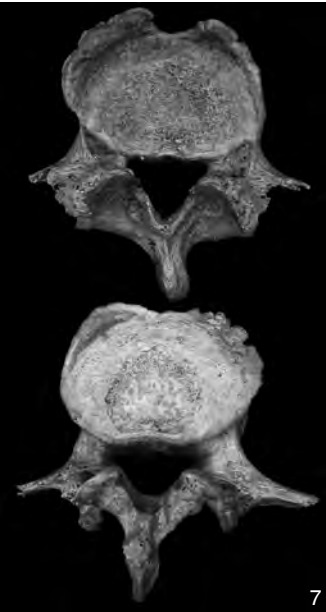
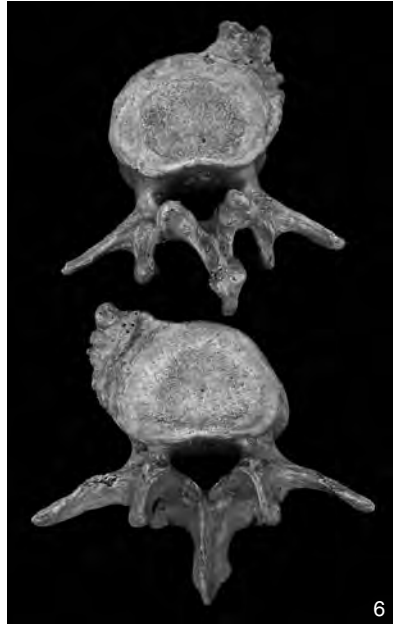
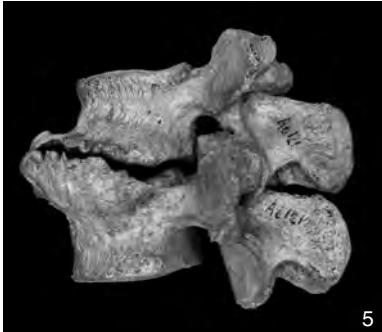
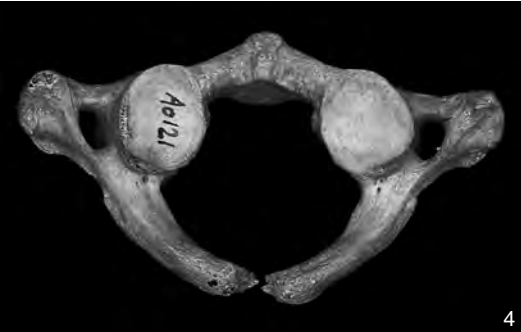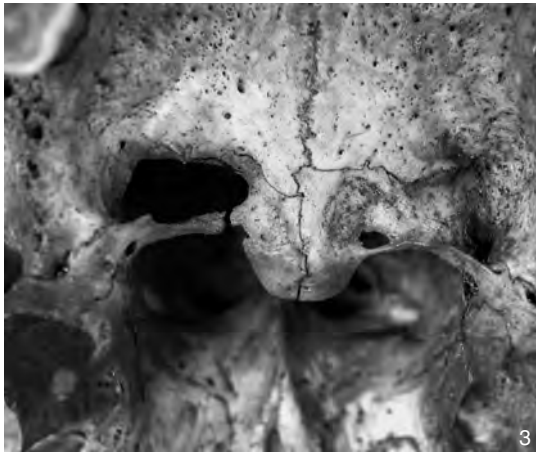
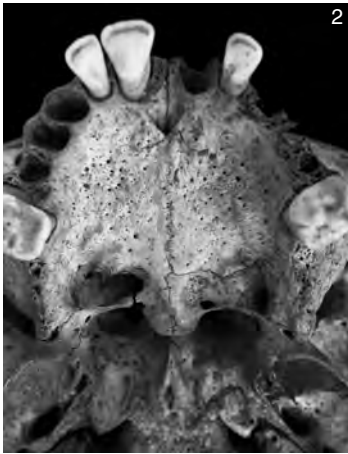


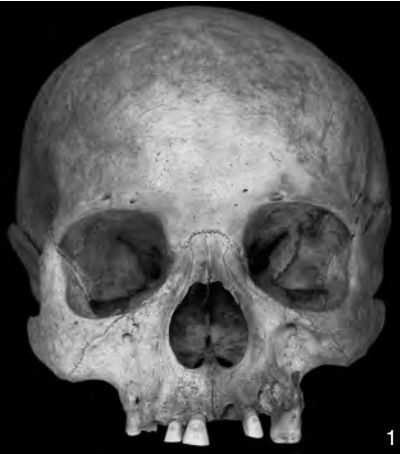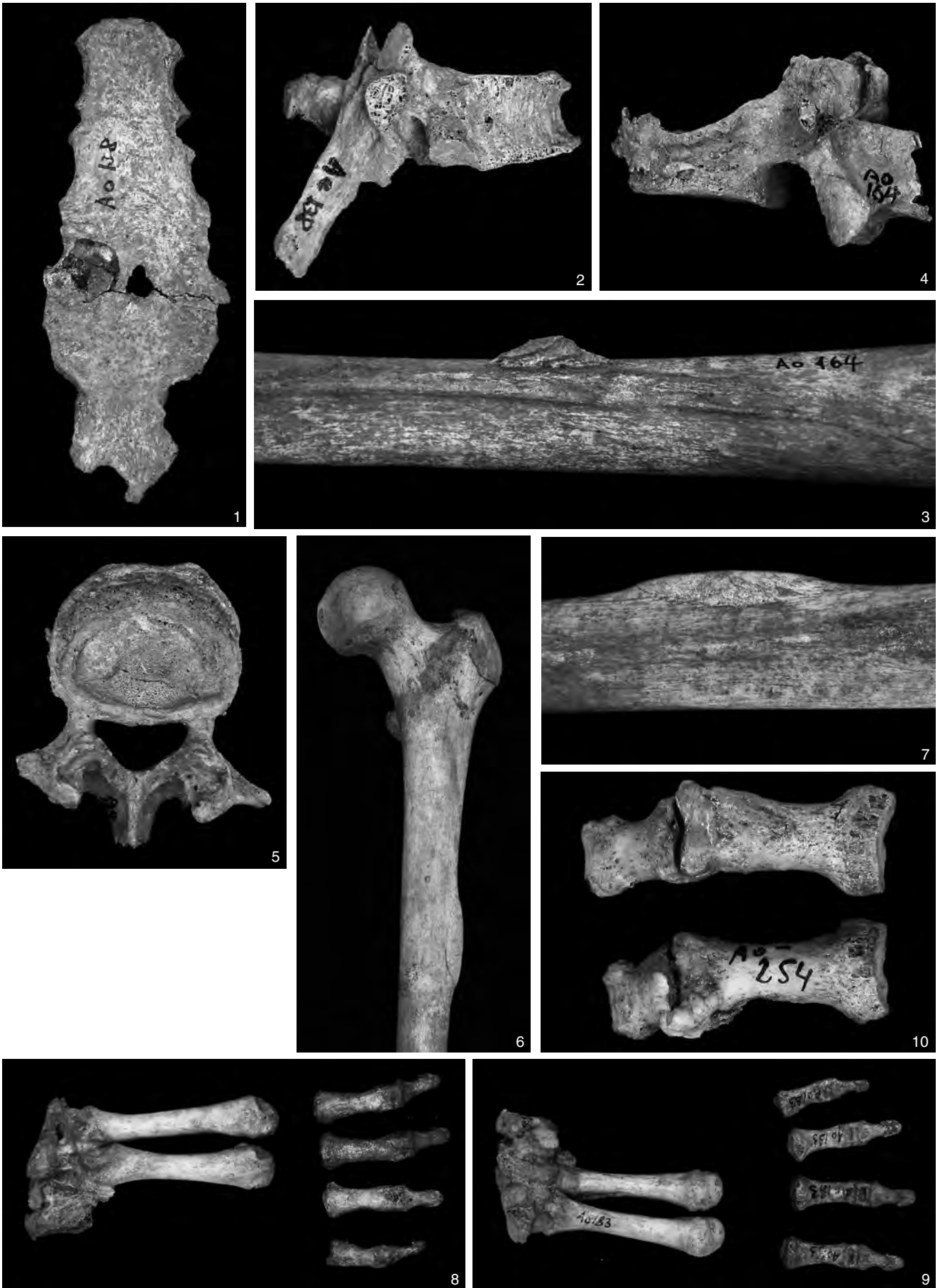PLATE 2



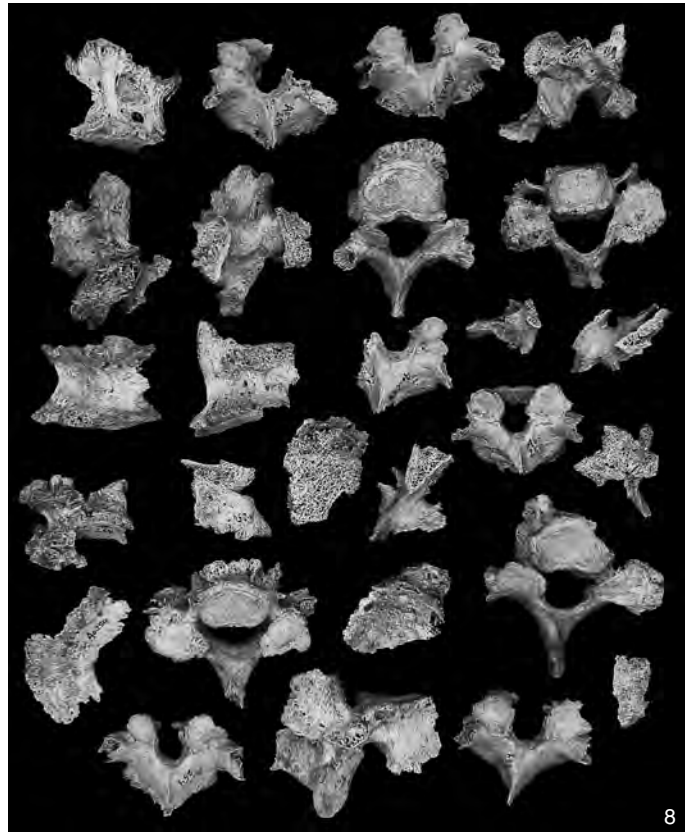
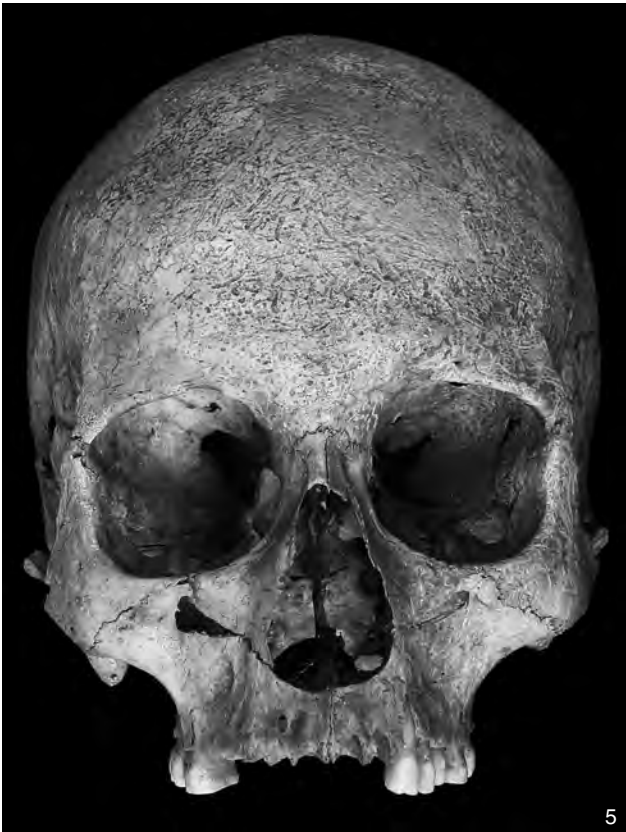
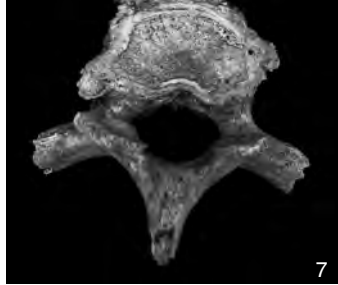
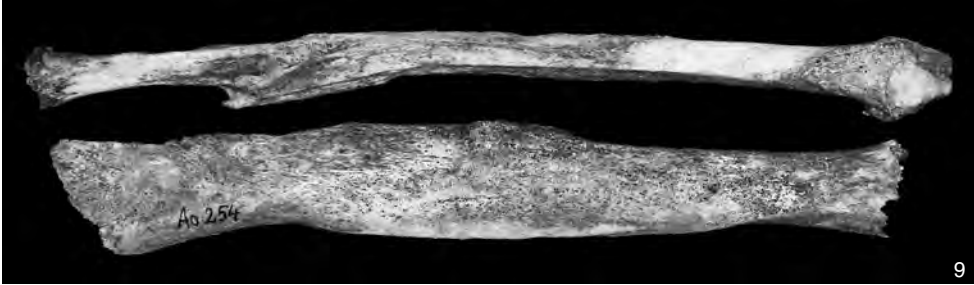
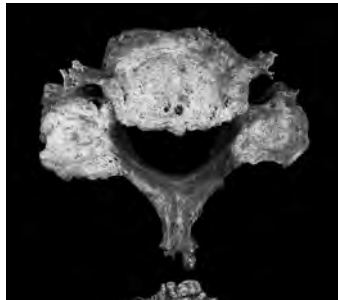
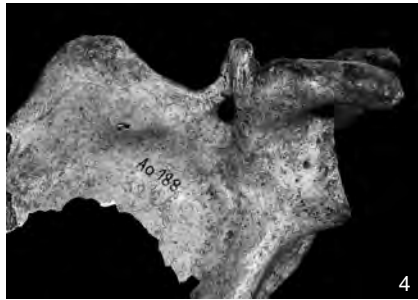
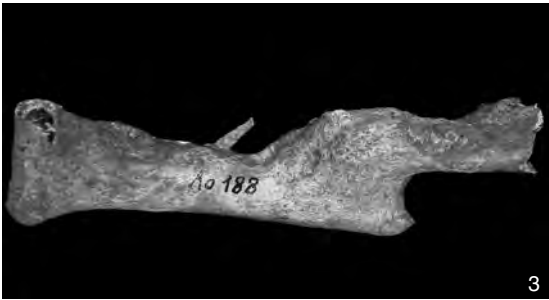
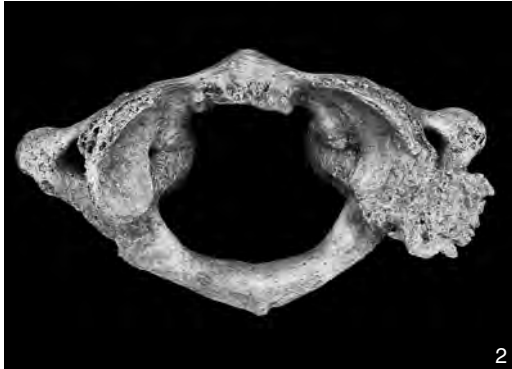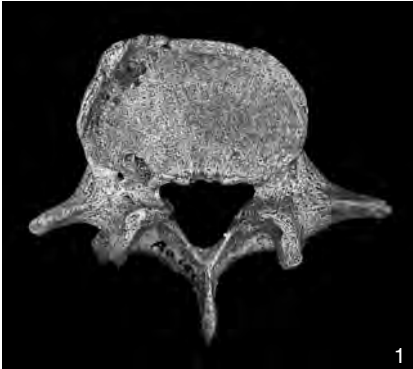
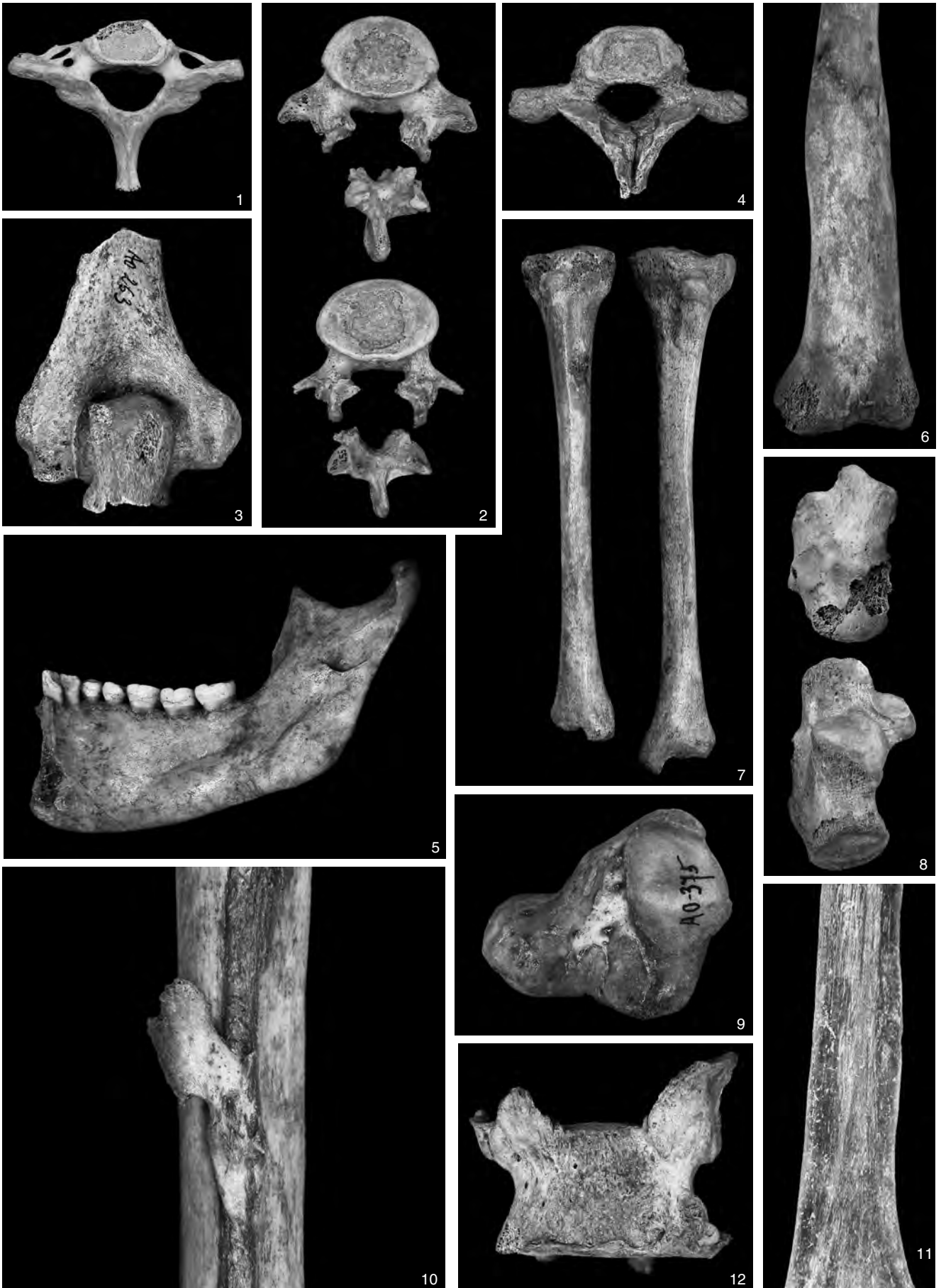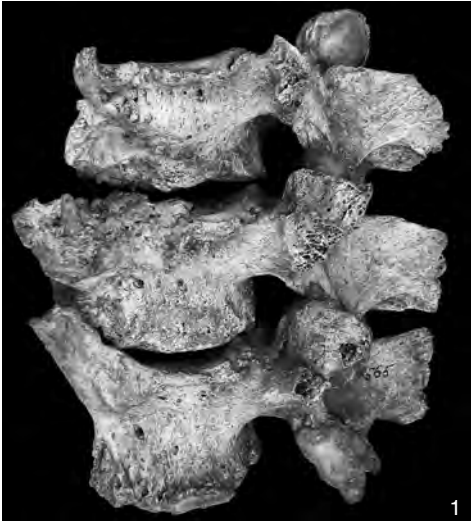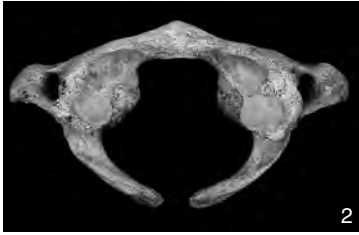


PLATE 4

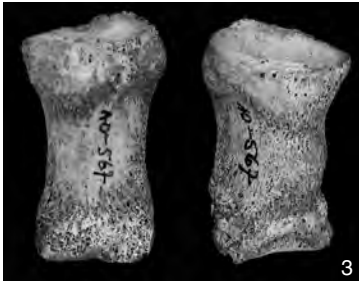



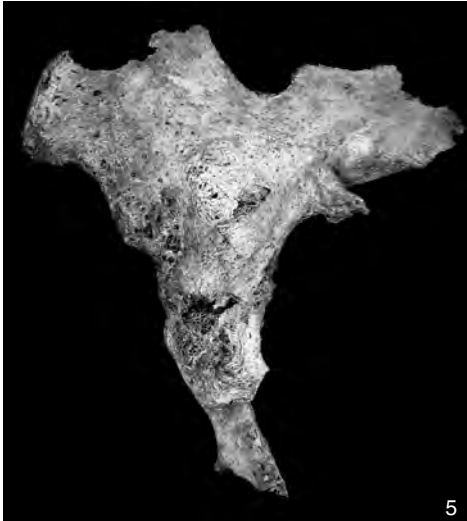1



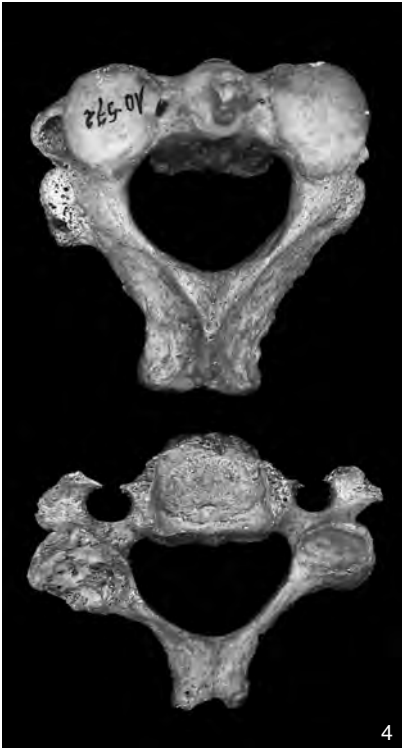2



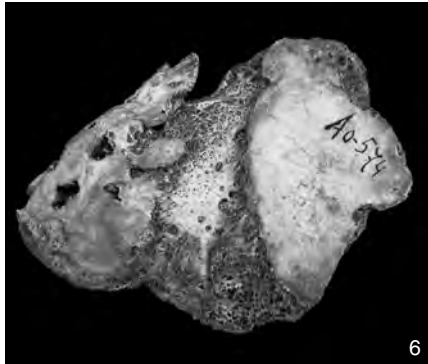3




5



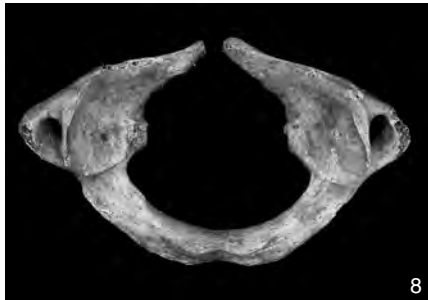4



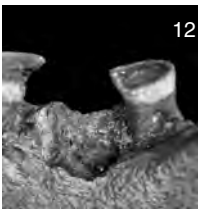
6



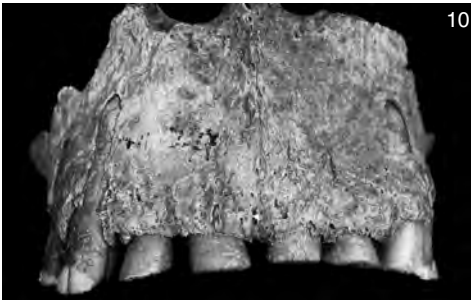
7



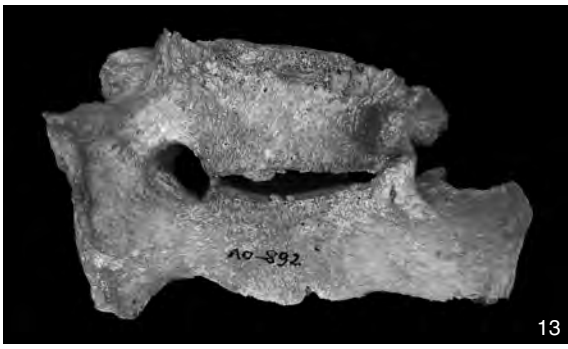
8



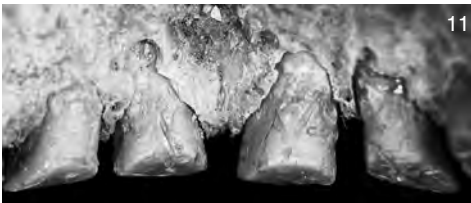
12



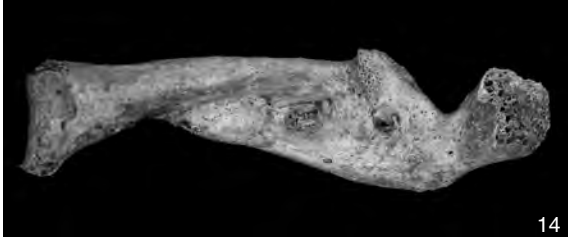10



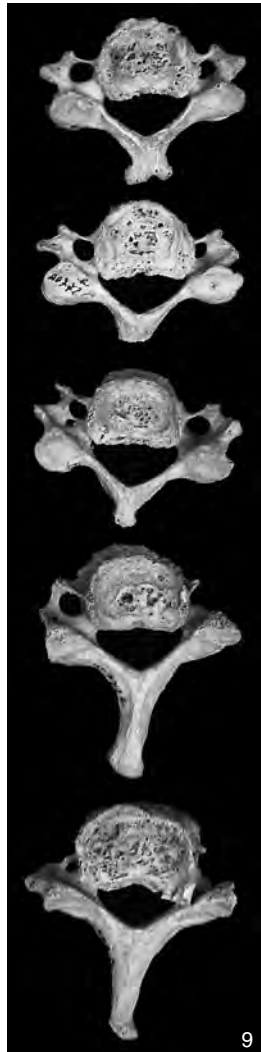
13



11




14



9

PLATE 6



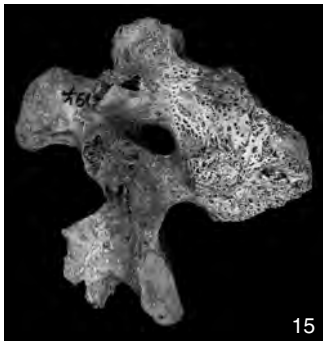
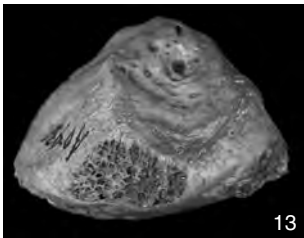
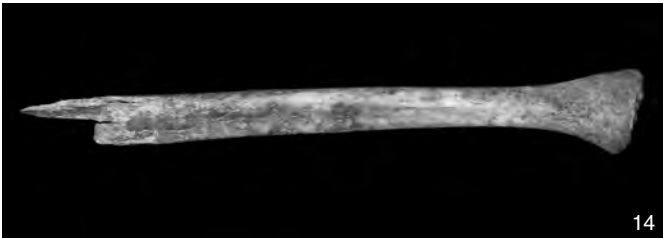
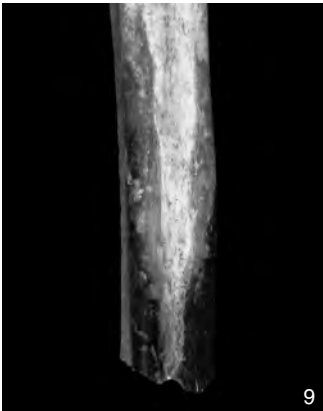
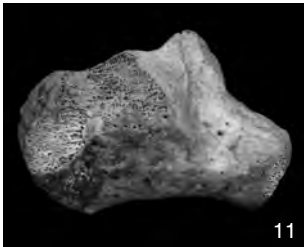

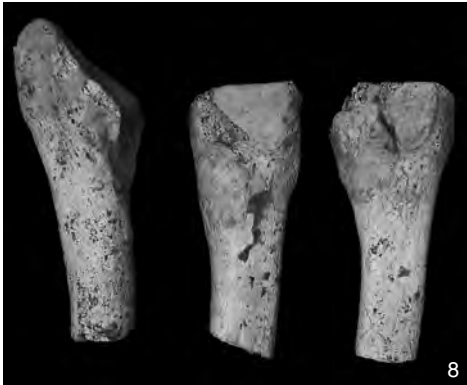
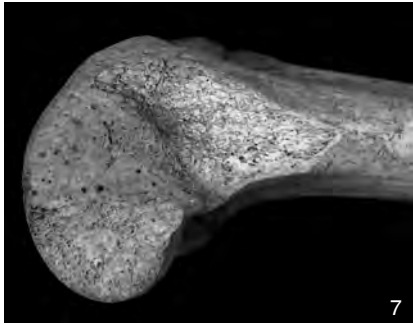
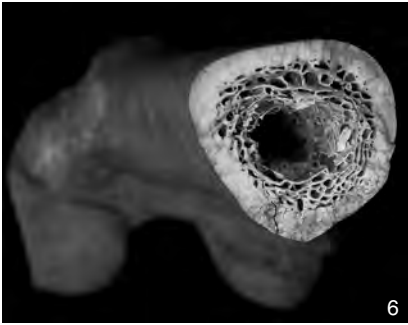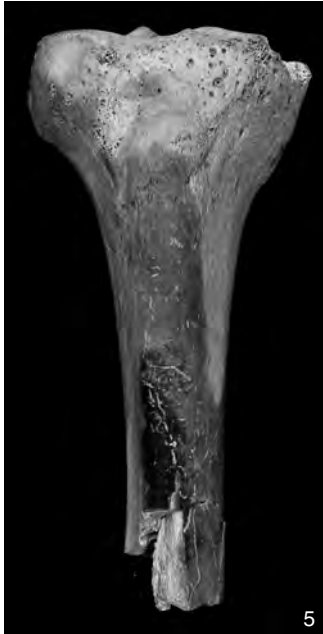
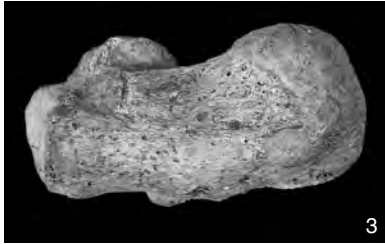
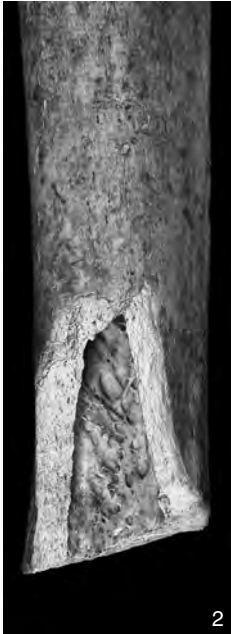
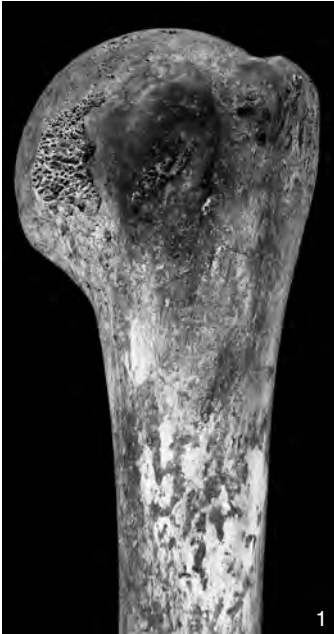
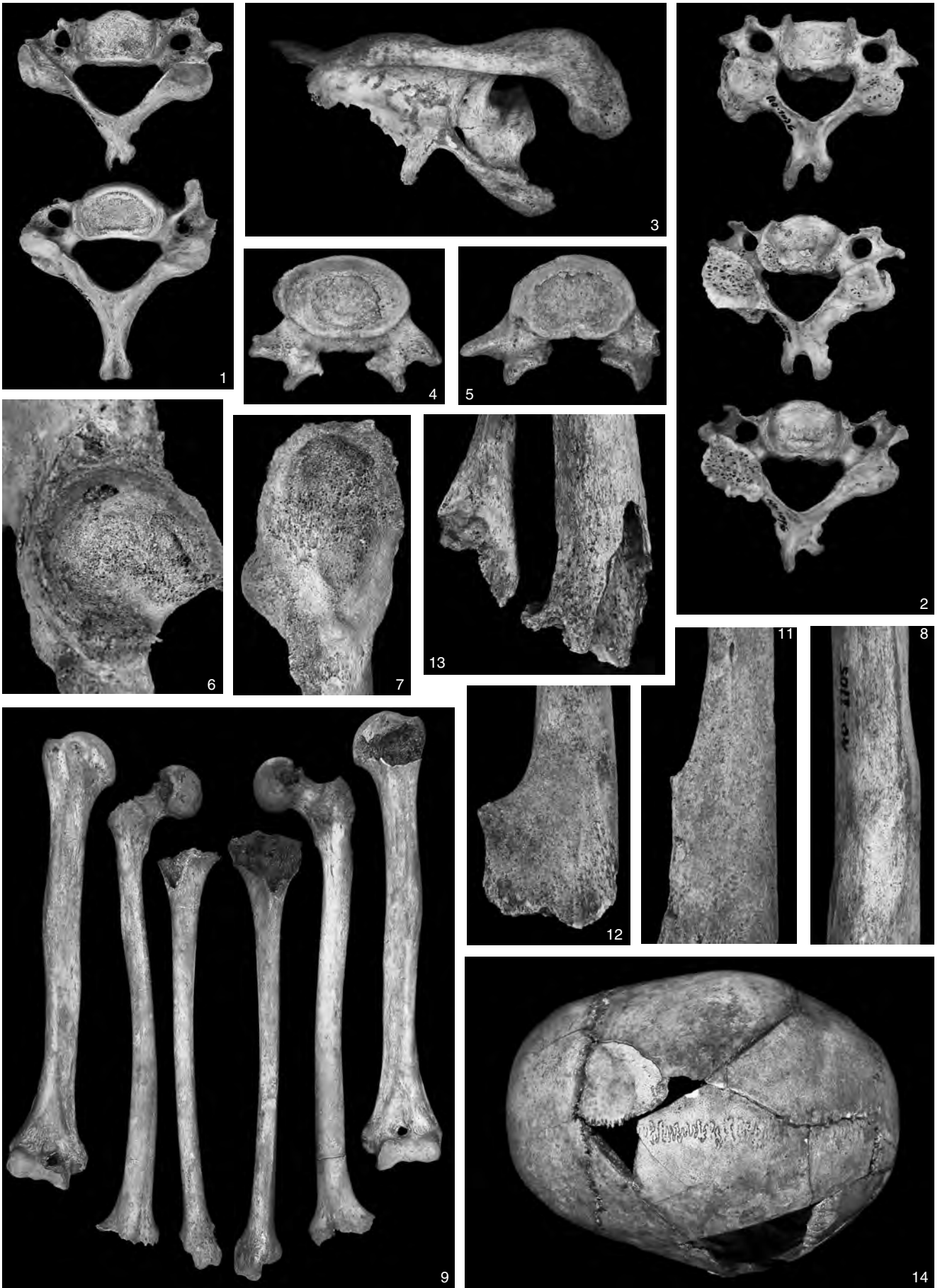PLATE 8



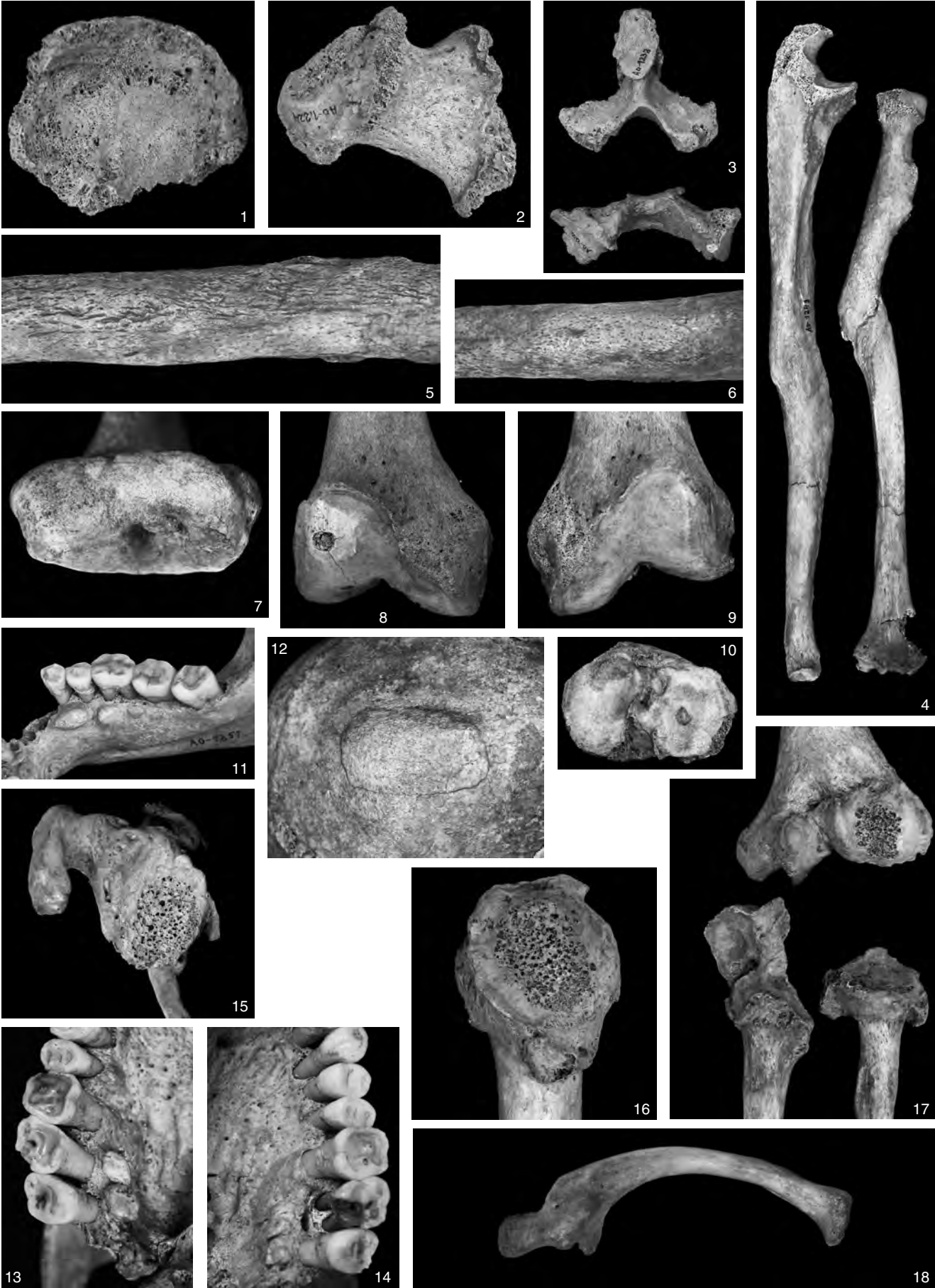
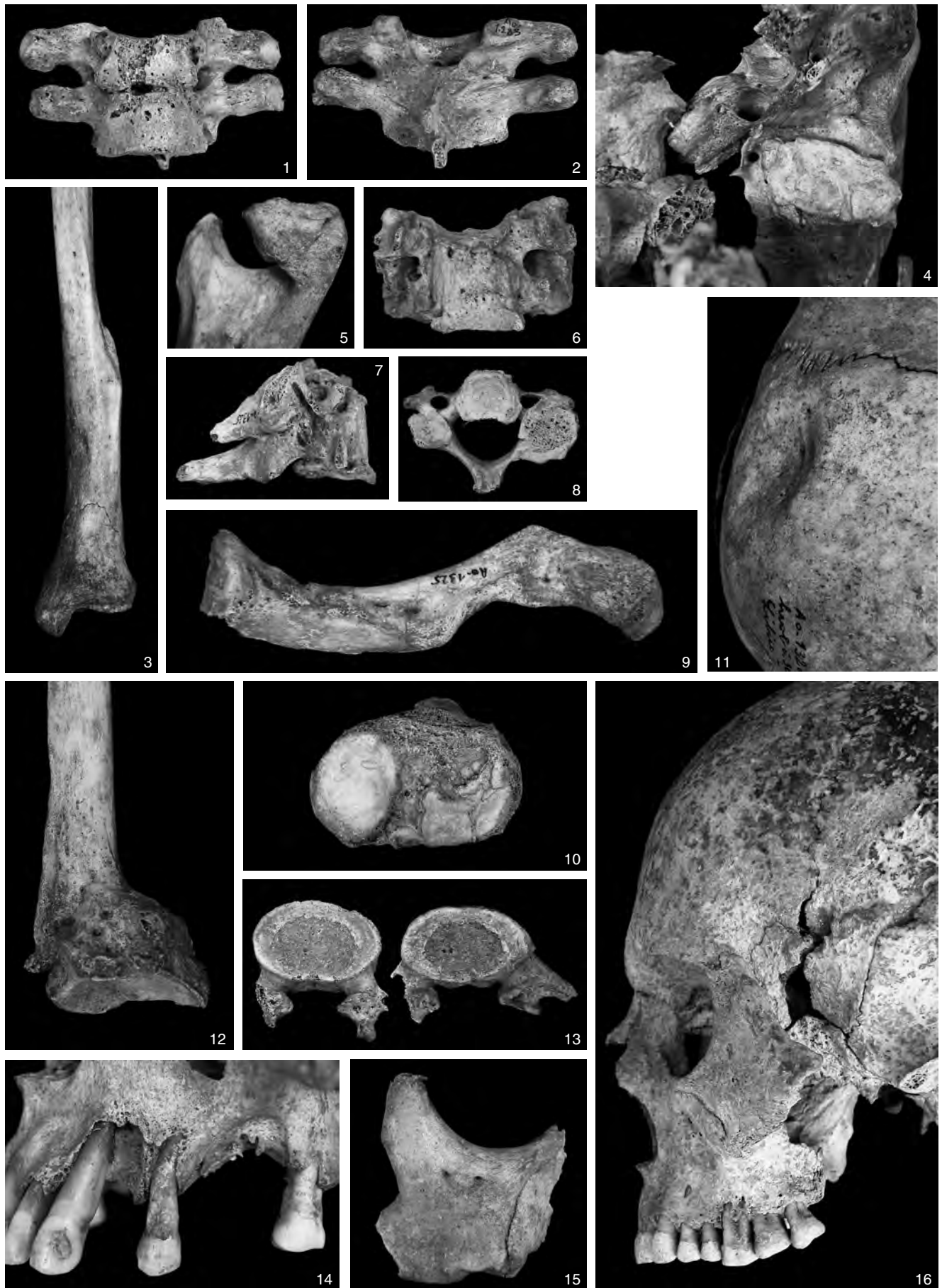


PLATE 10



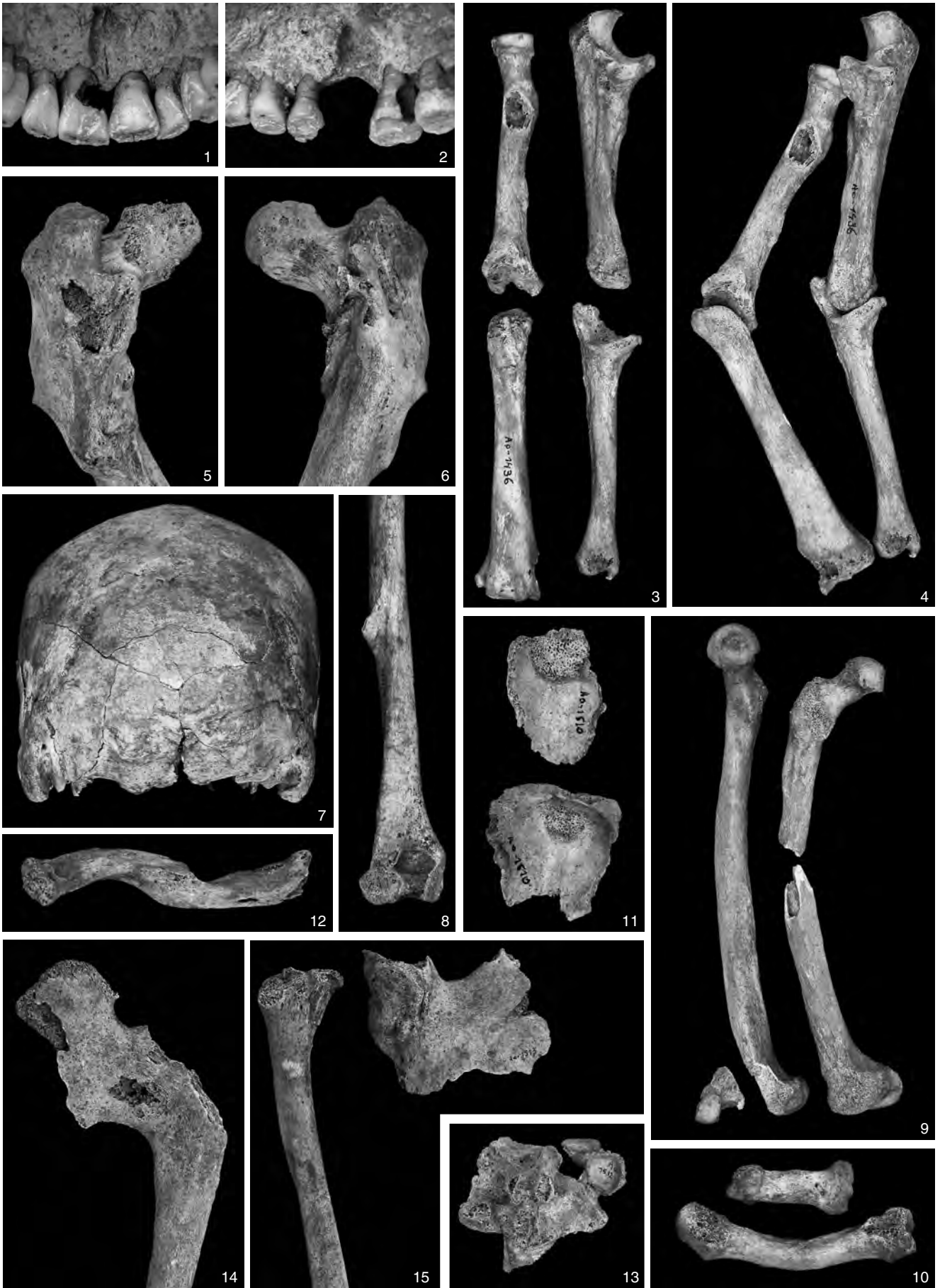
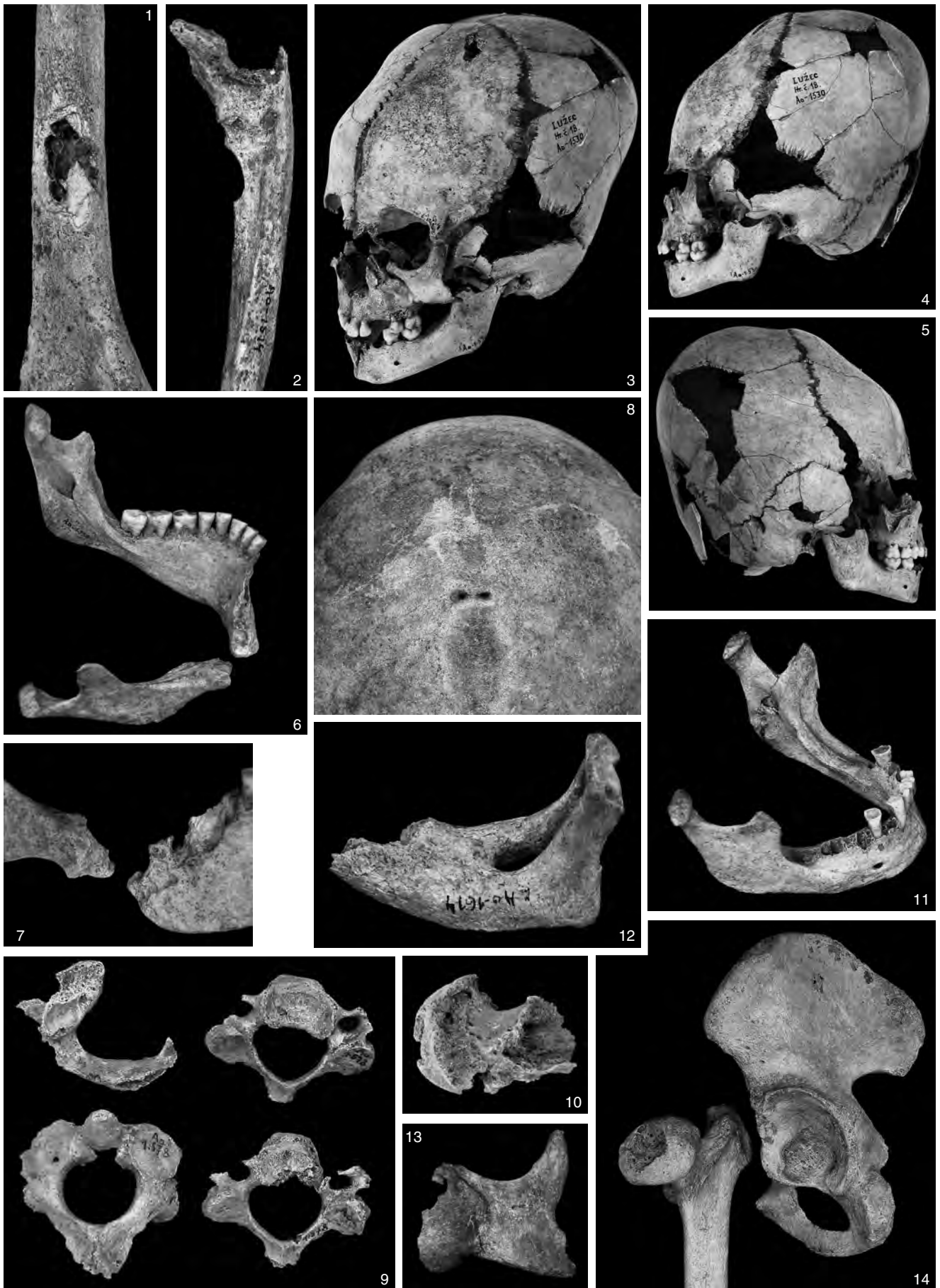

PLATE 12



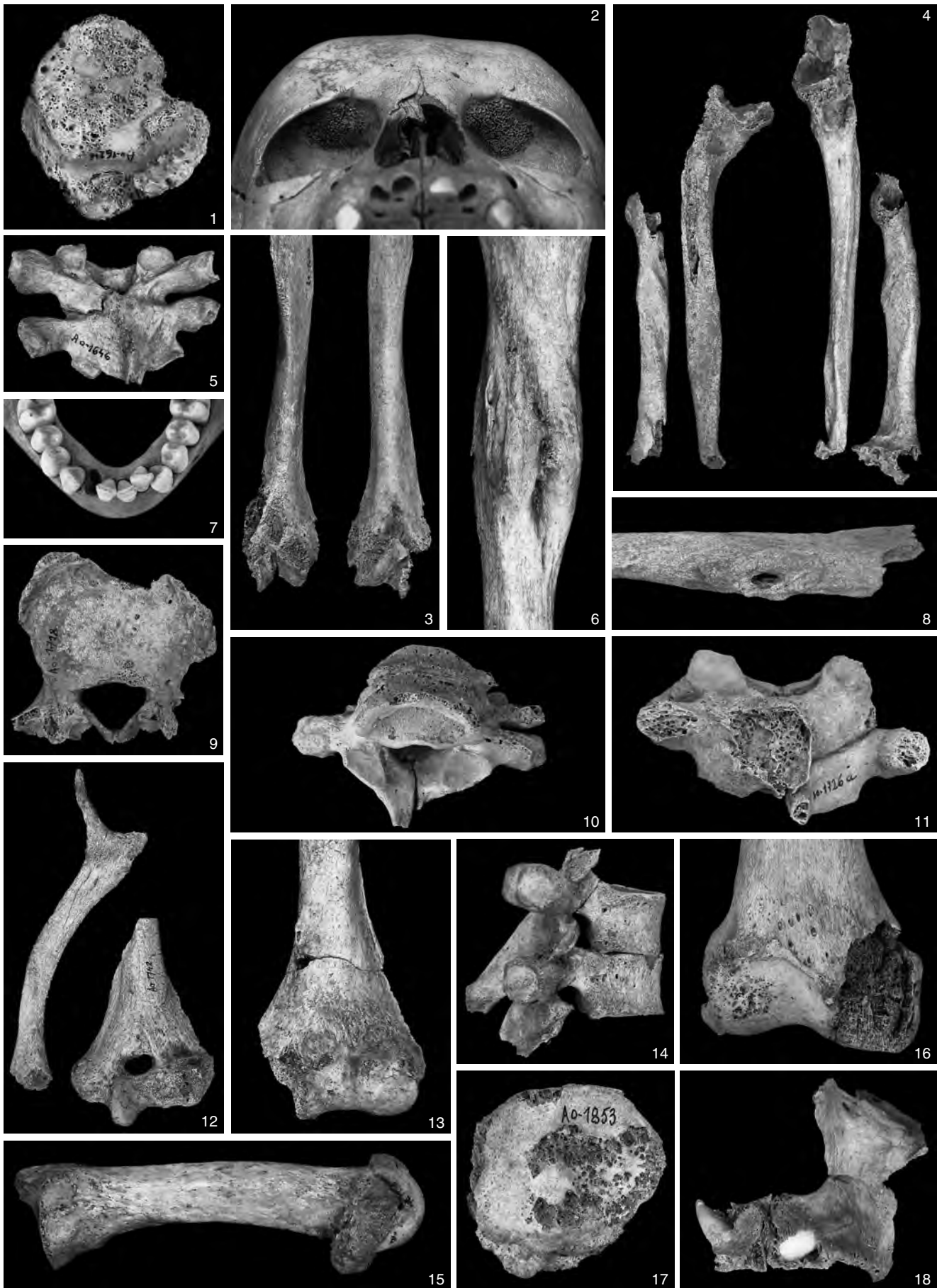
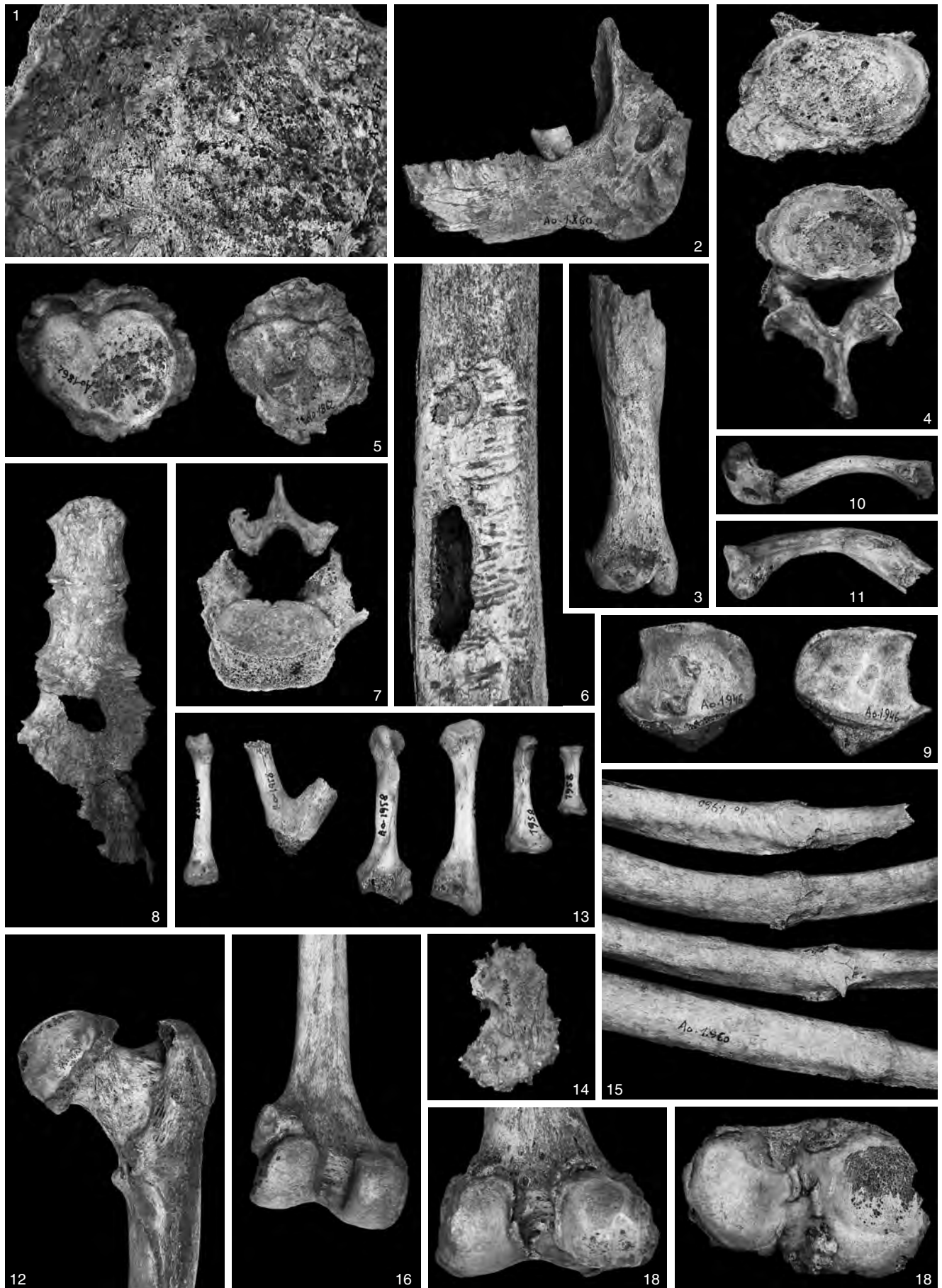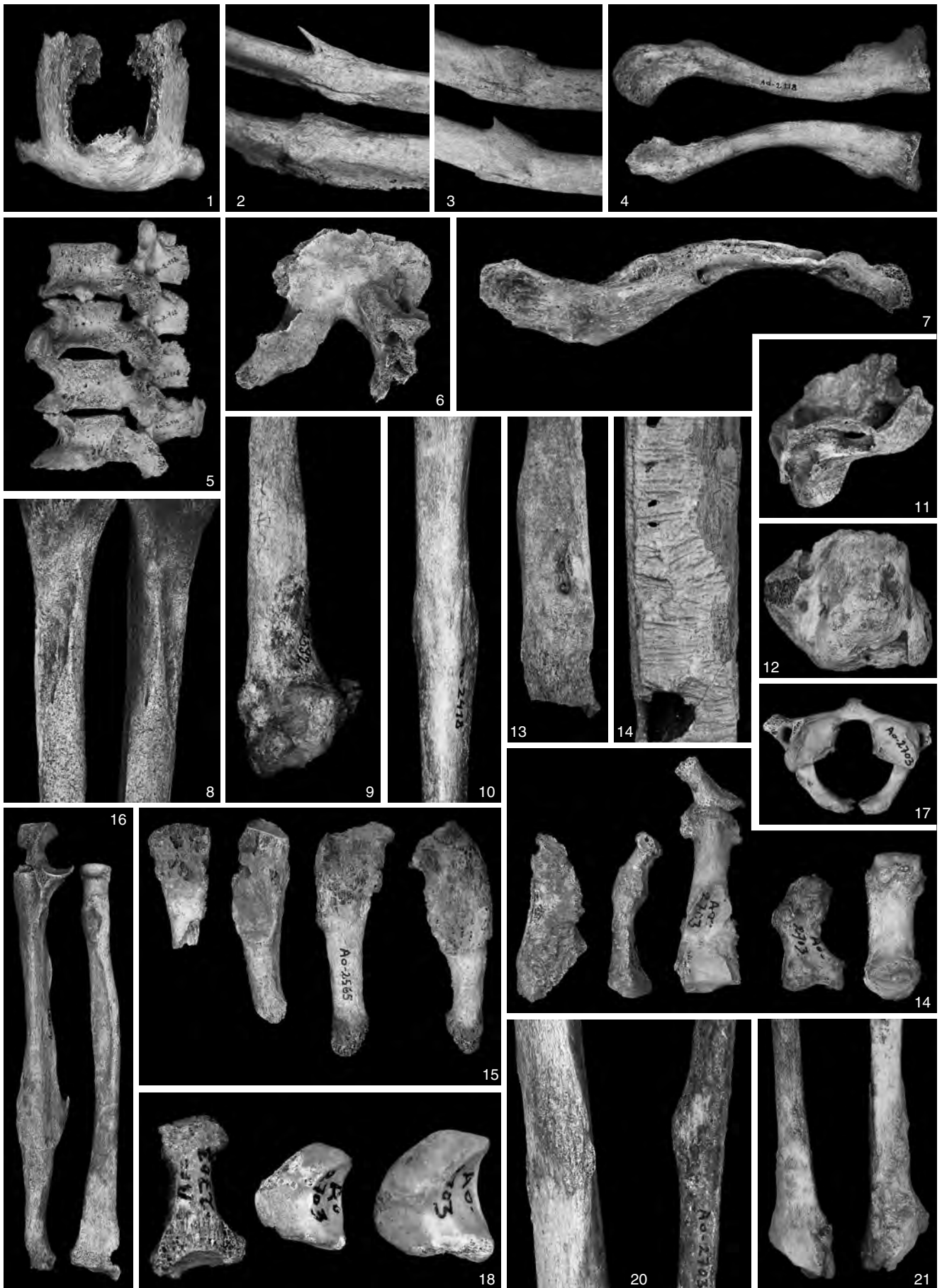


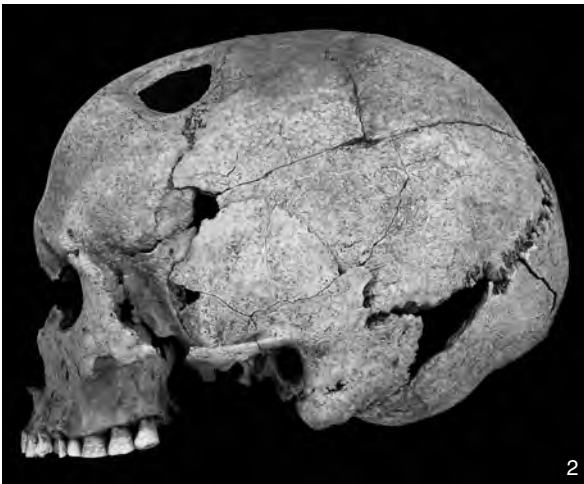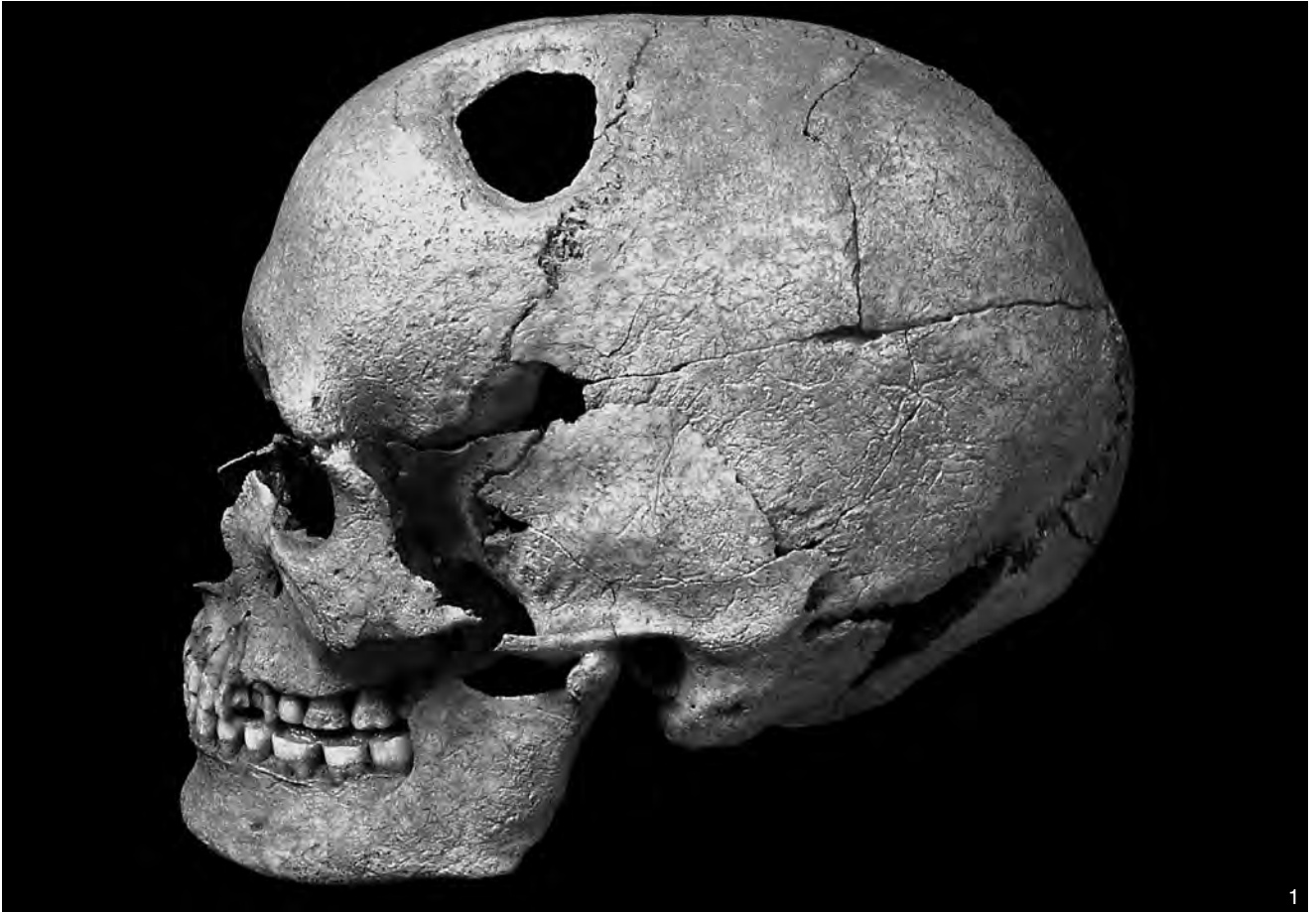PLATE 14






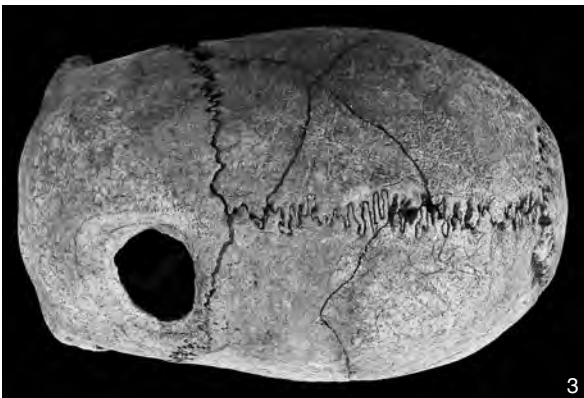
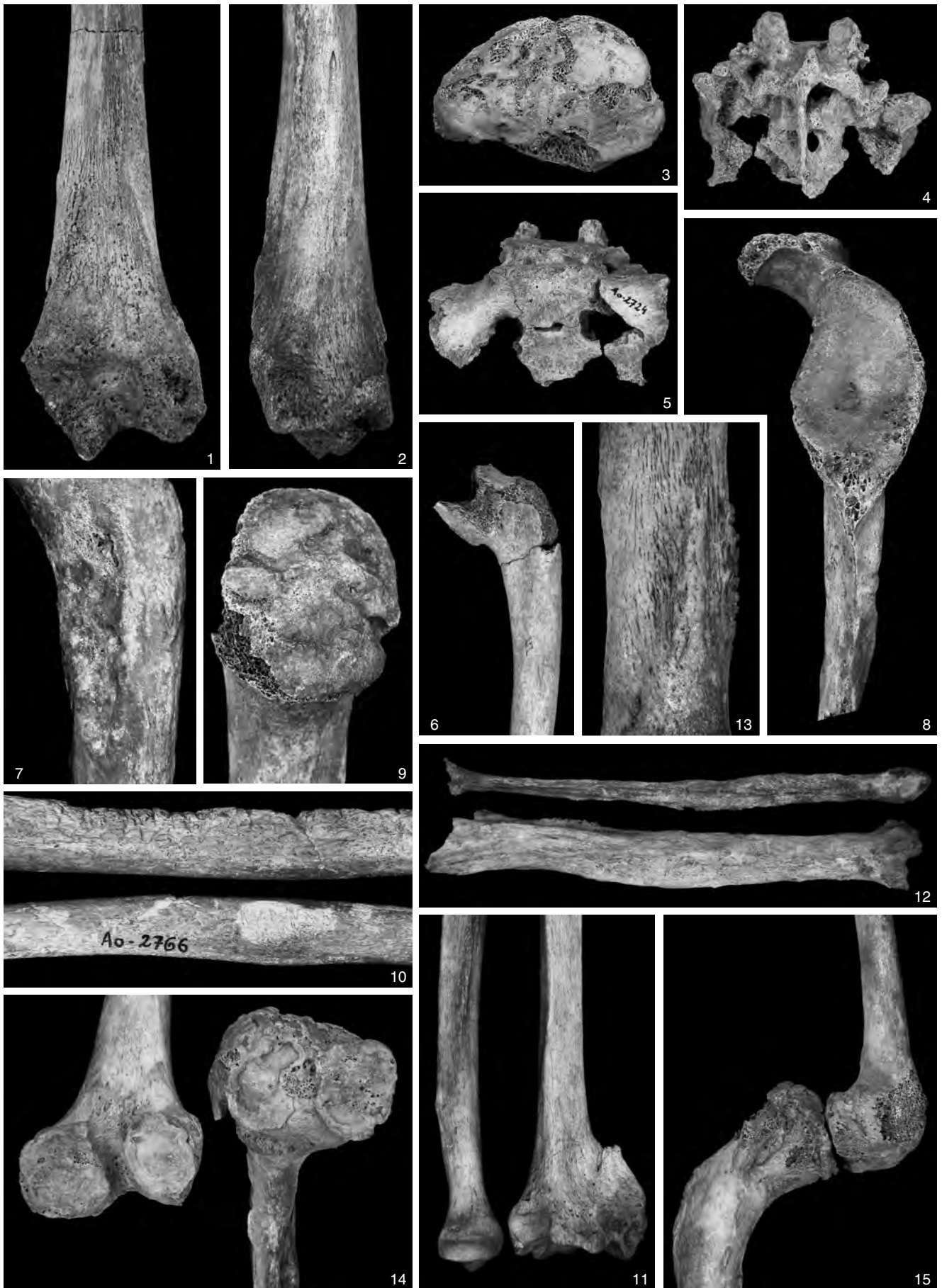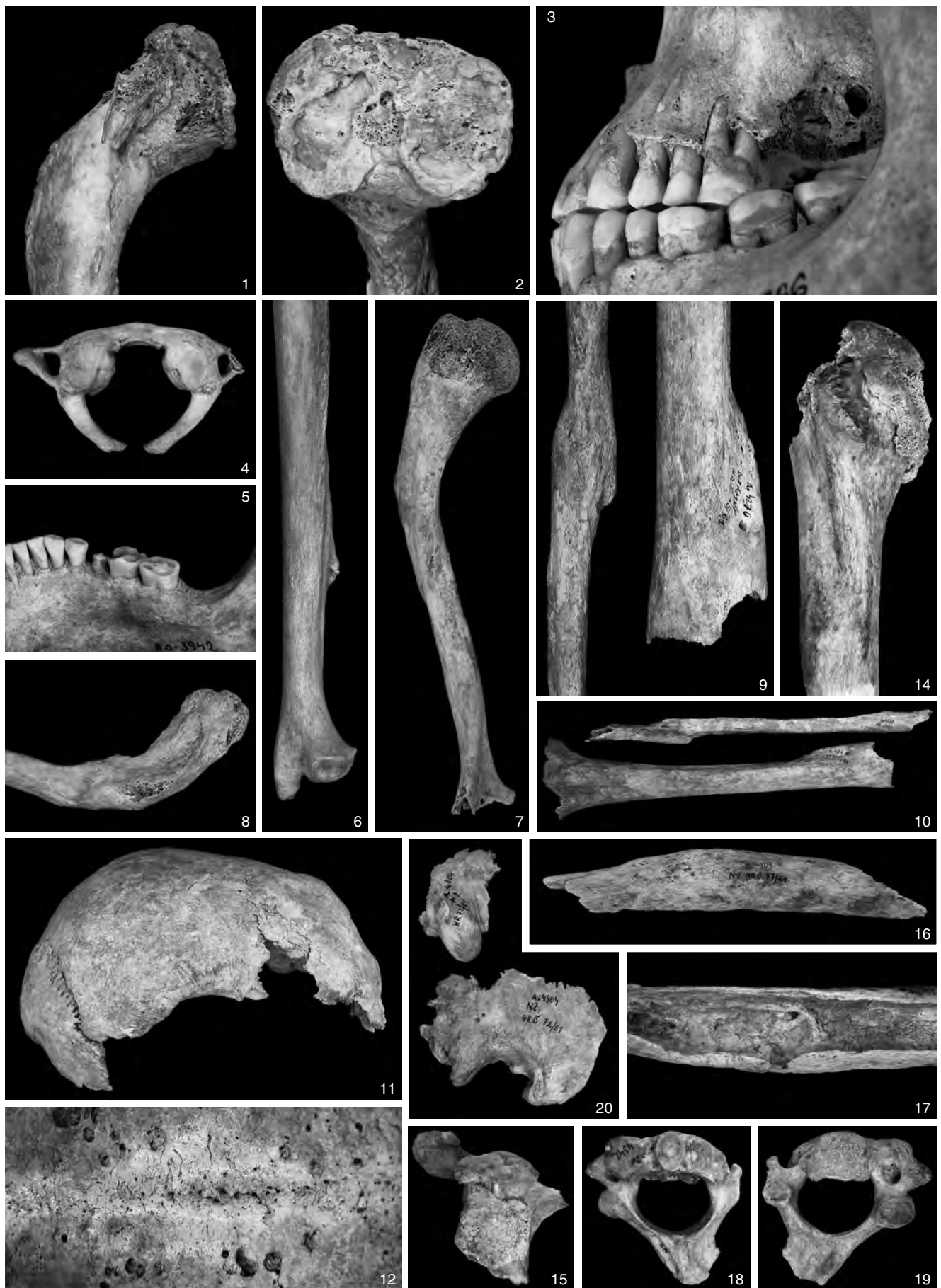




PLATE 18



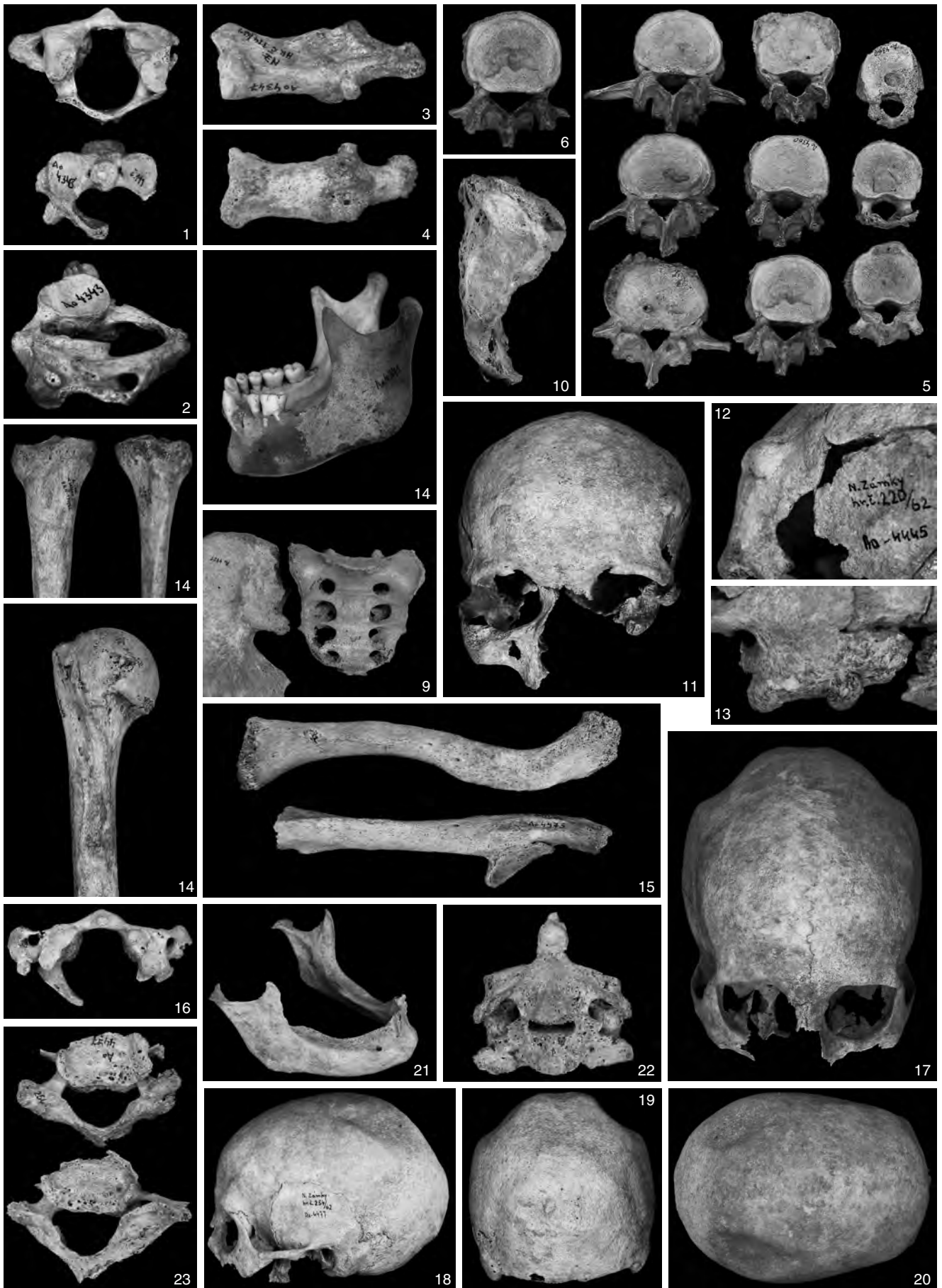
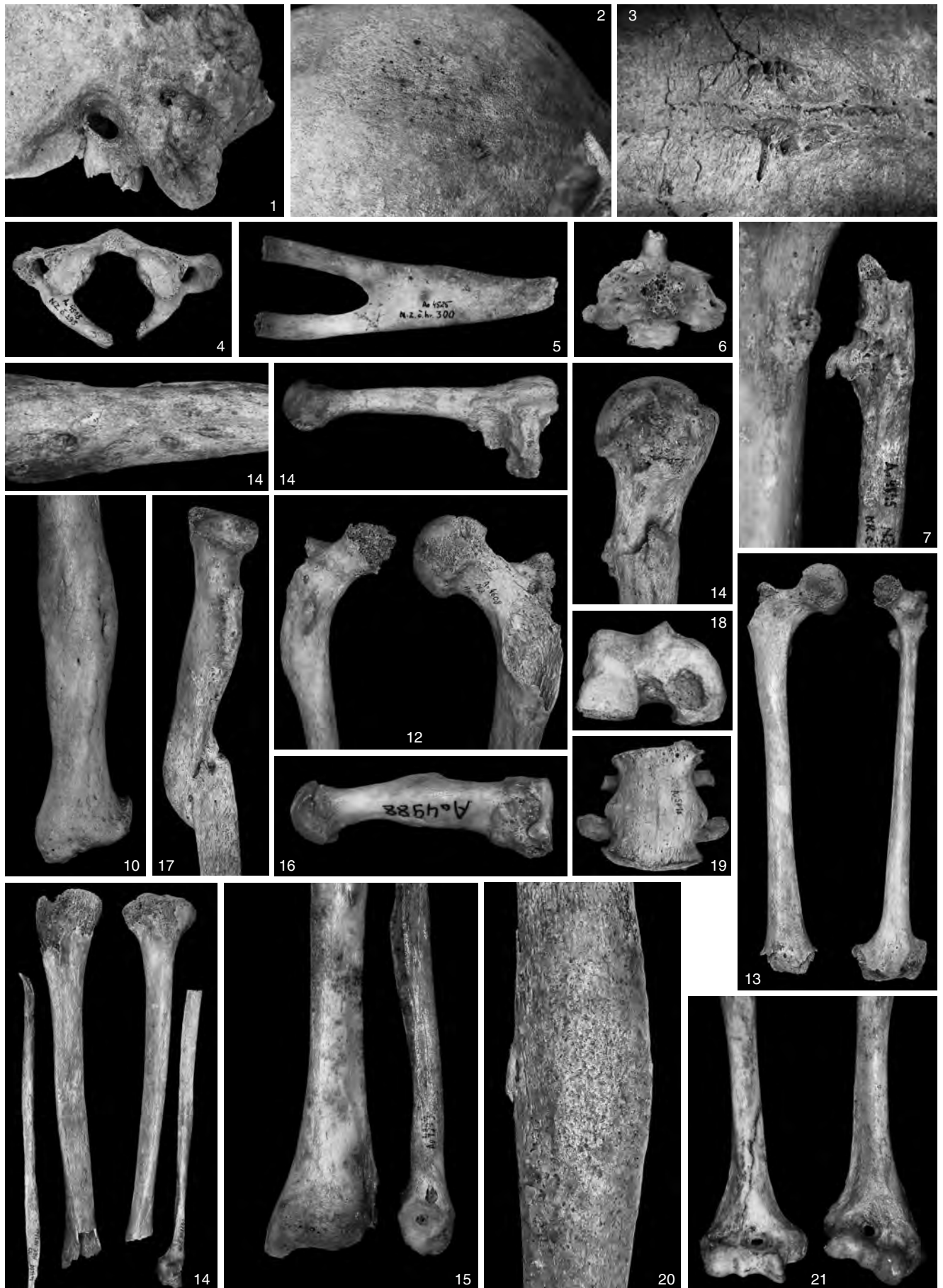


PLATE 20



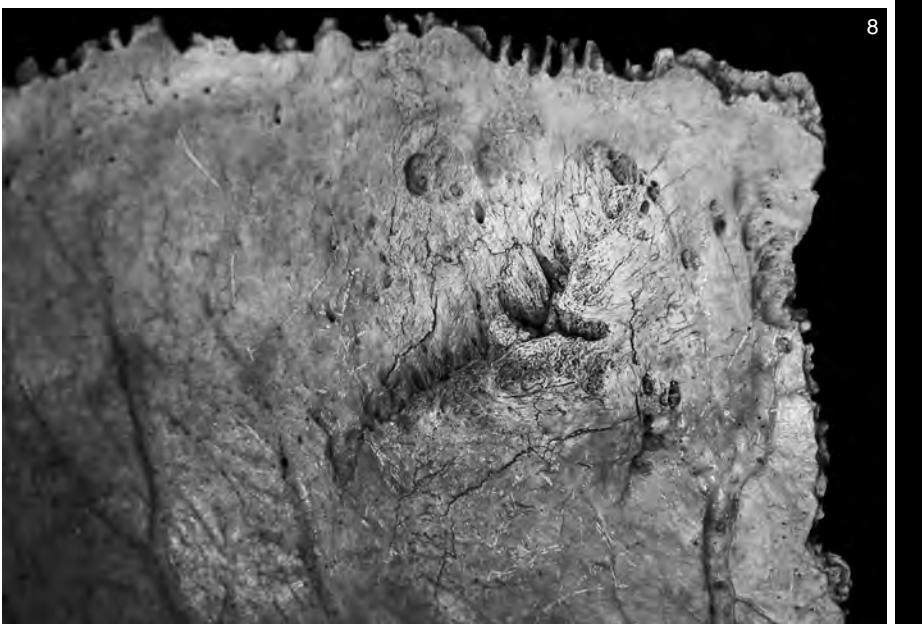
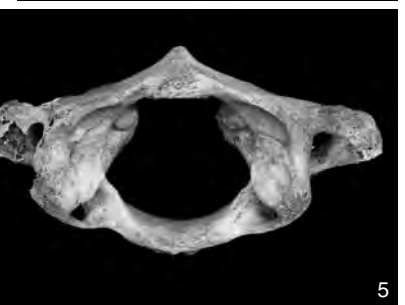
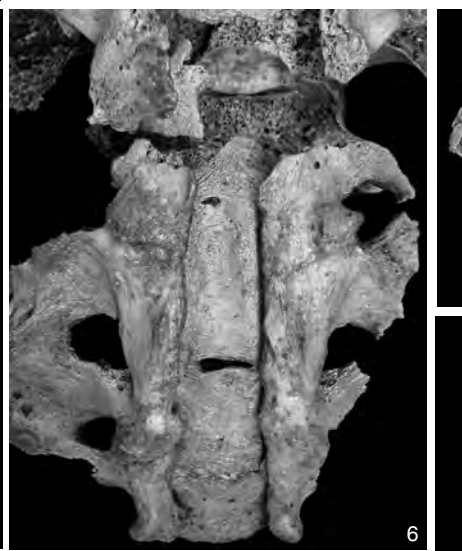
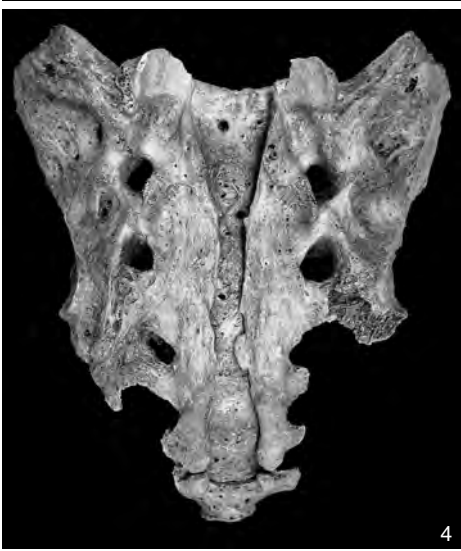
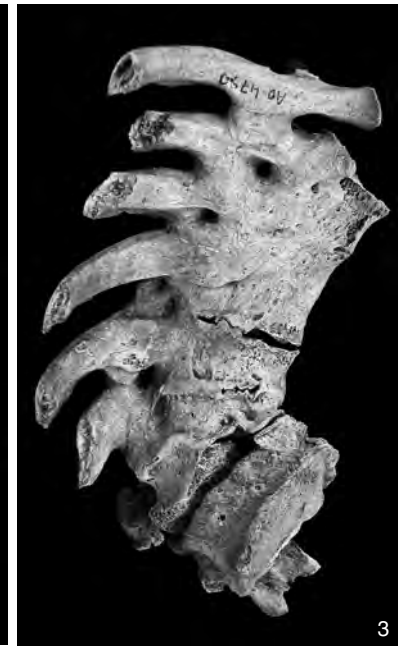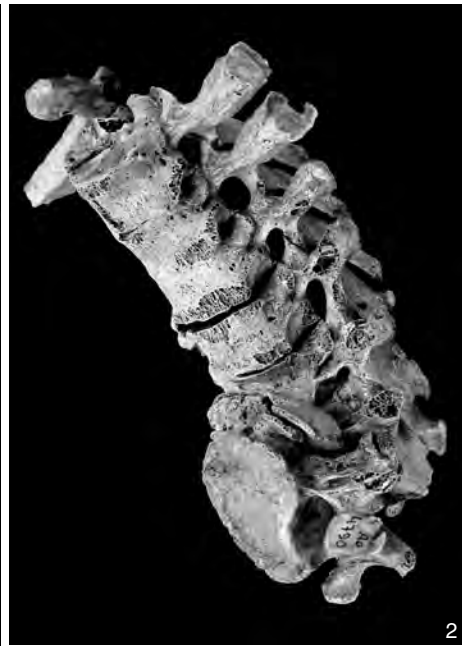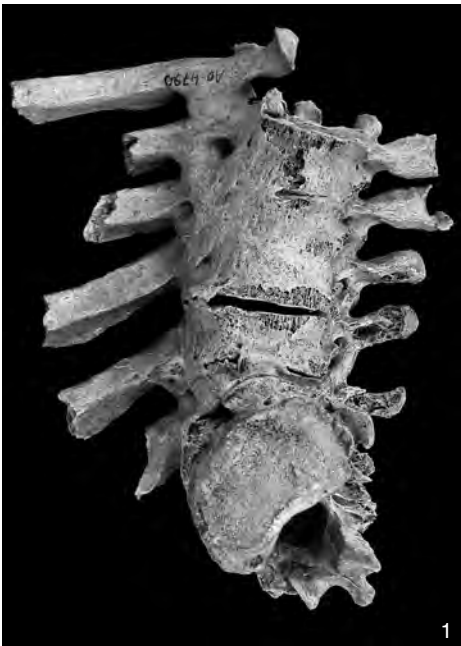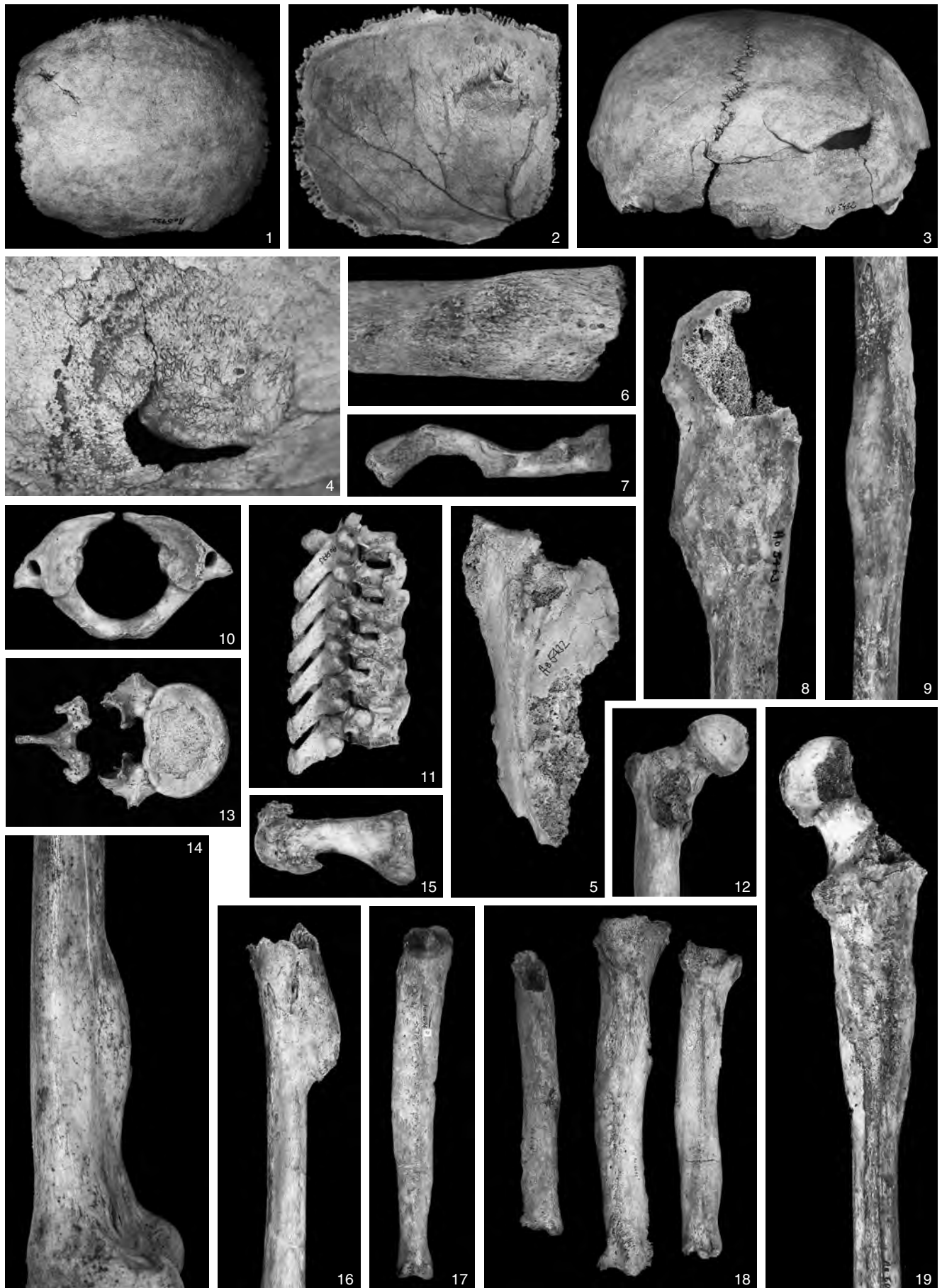PLATE 22



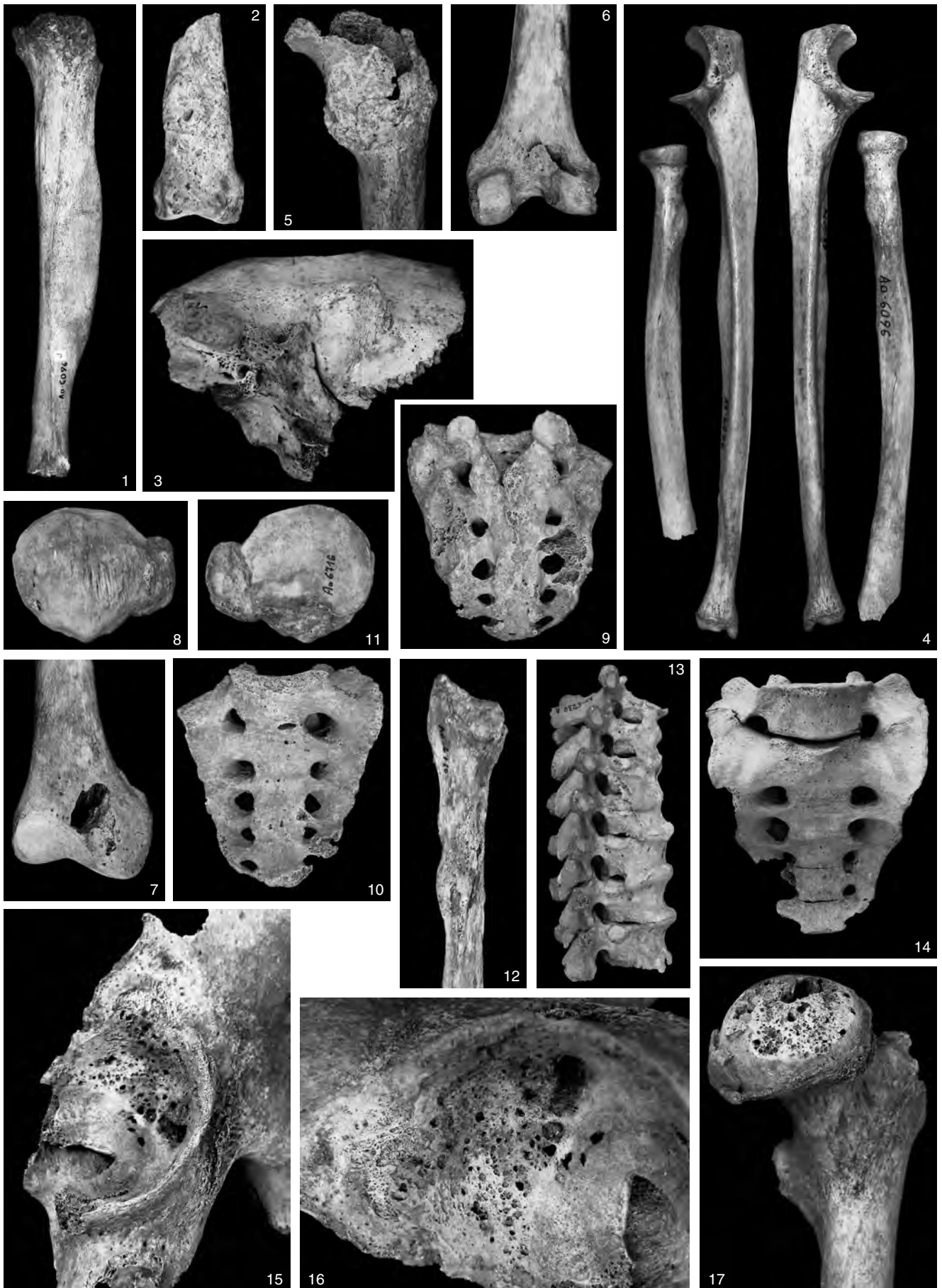
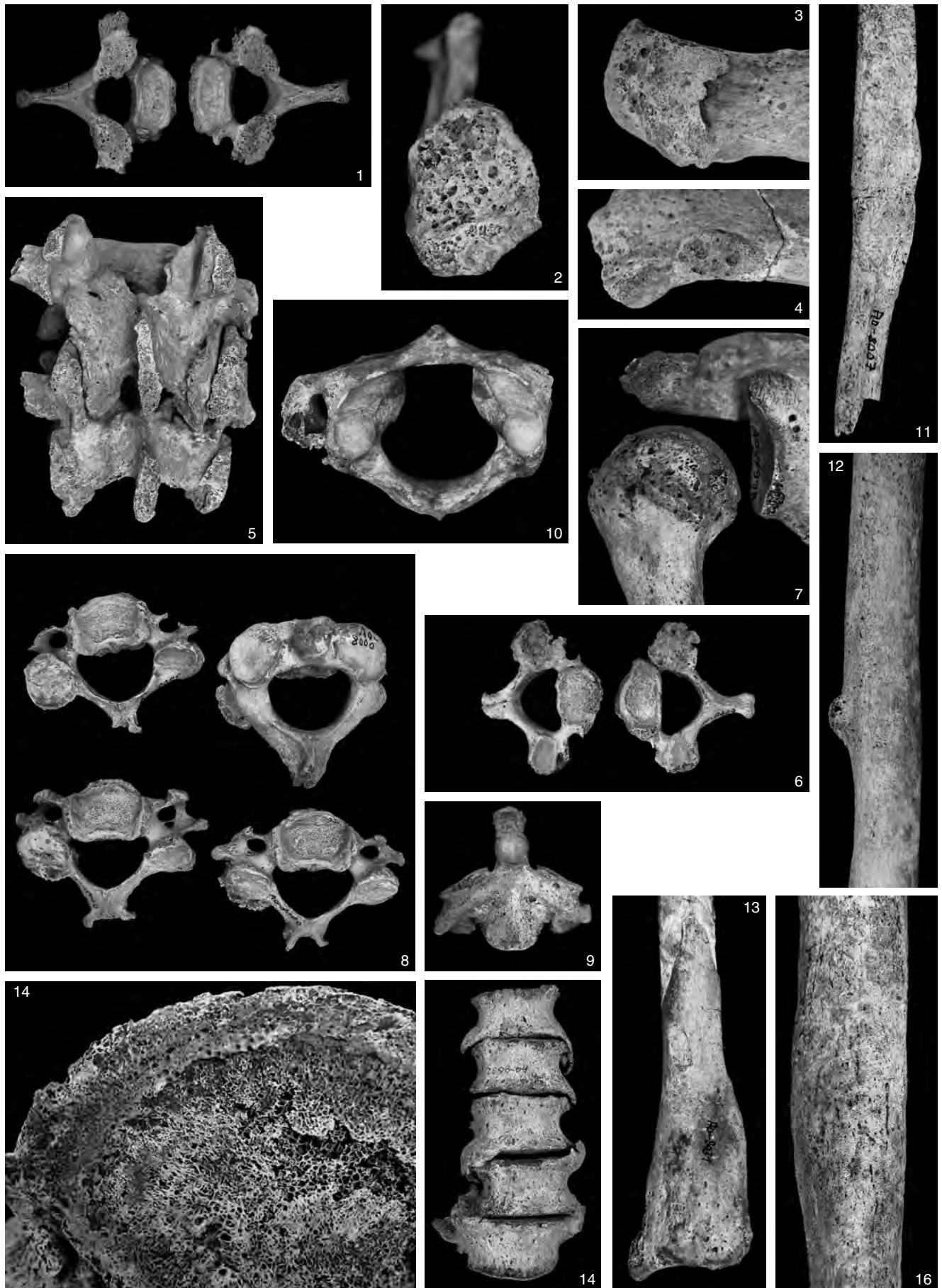


PLATE 24



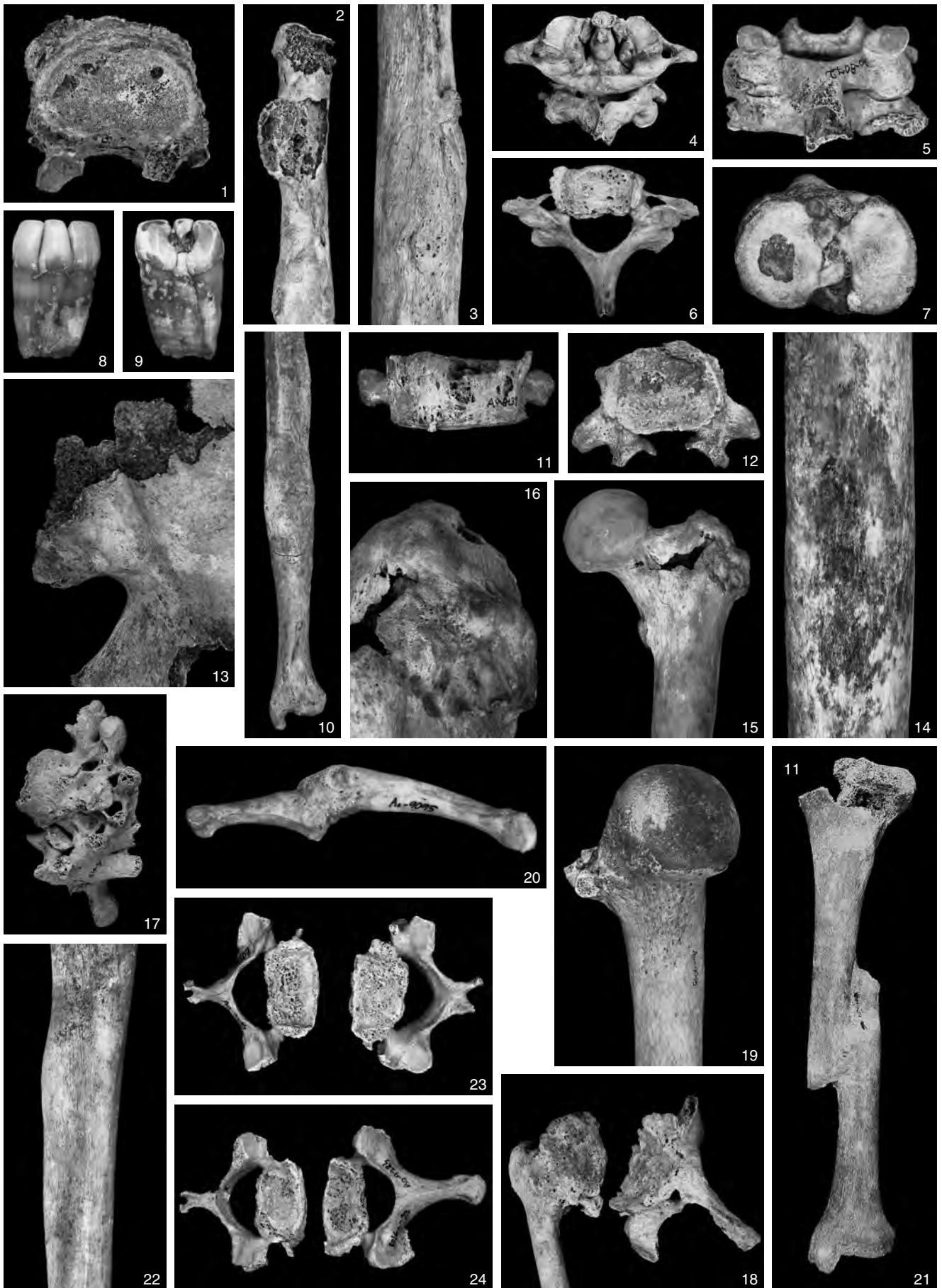
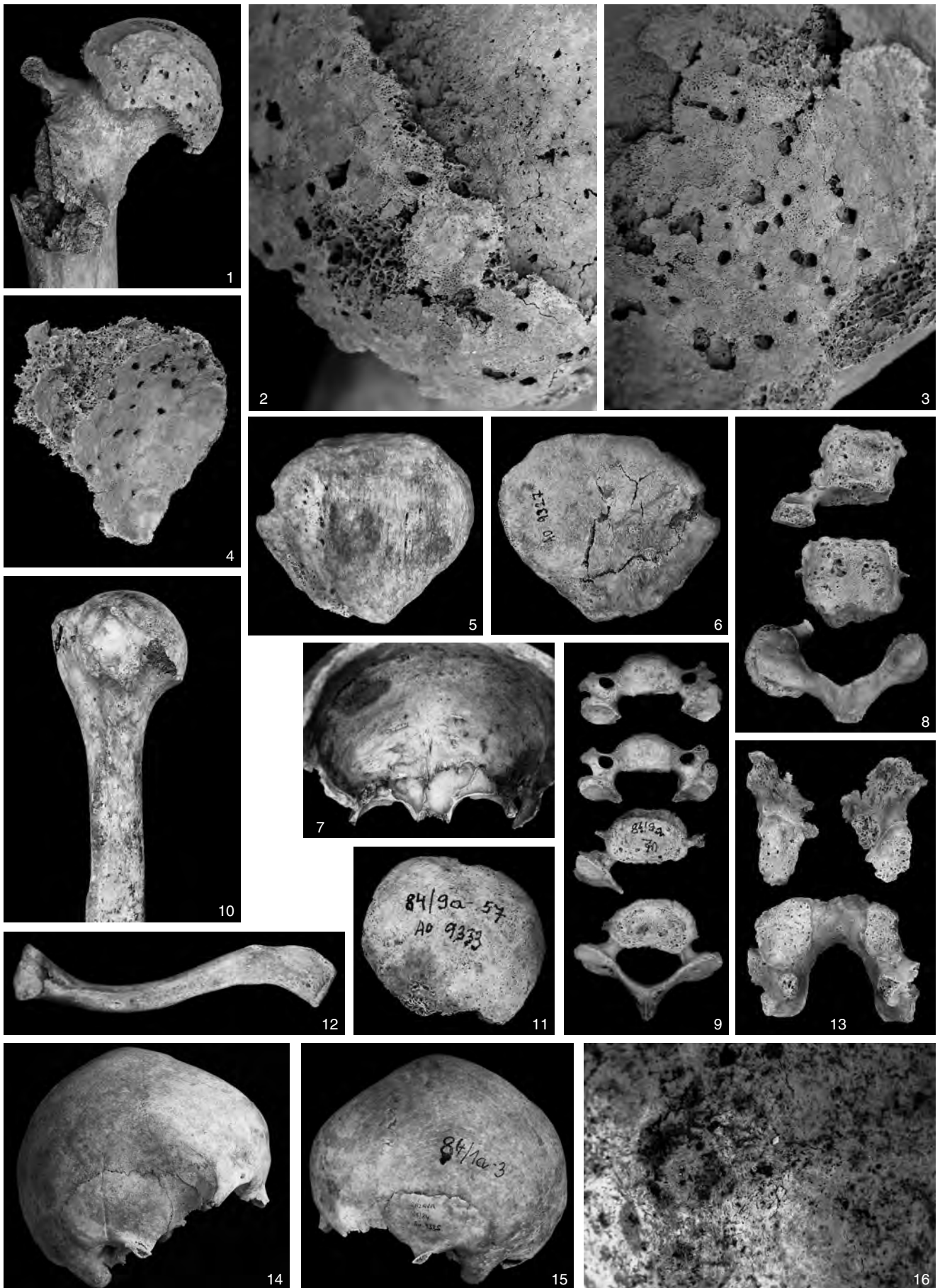
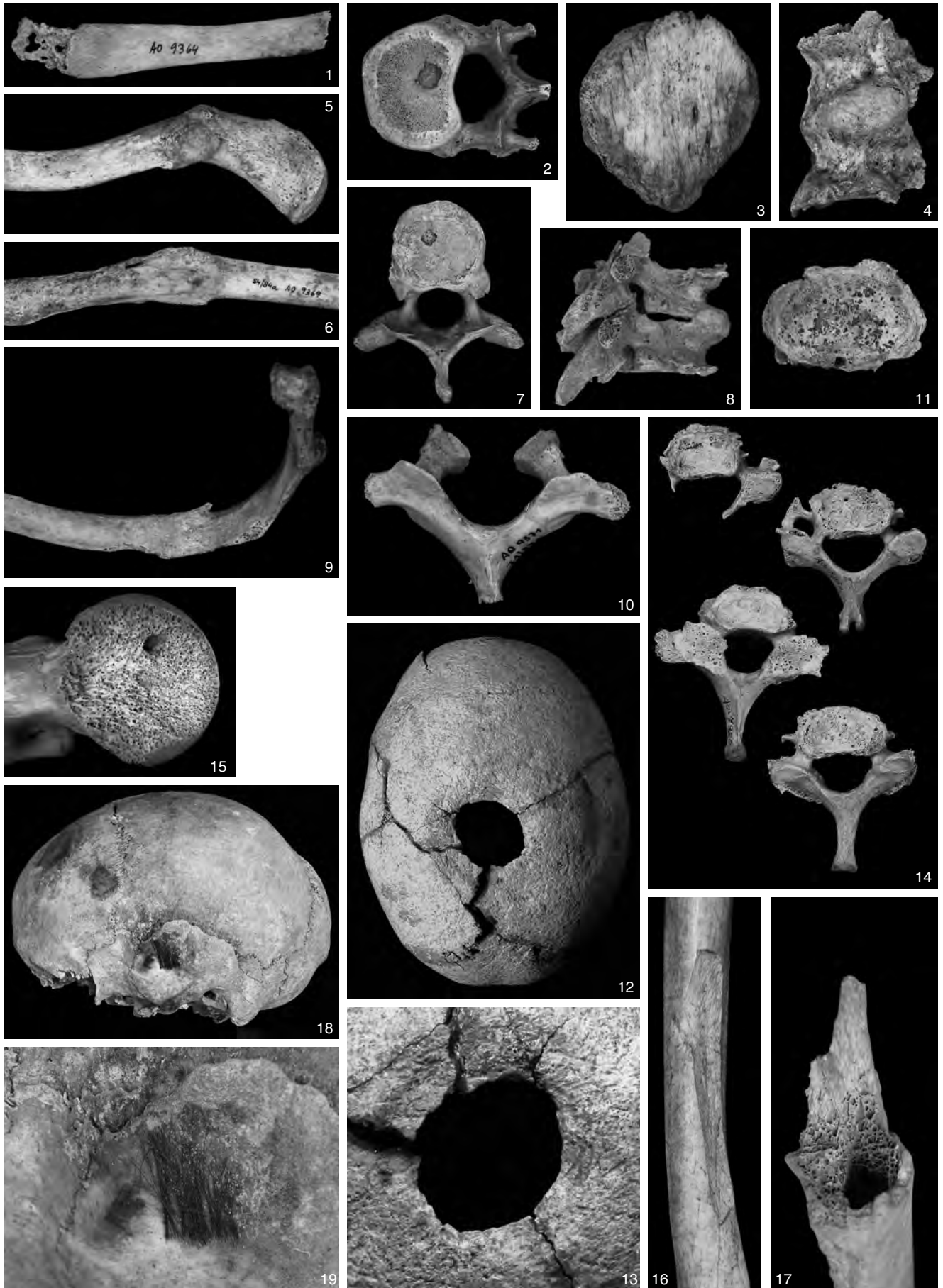


PLATE 26





CONTENTS

Jakub Likovský – Petra Stránská – Petr Velemínský

An Assortment of Palaeopathological Findings from the Anthropological Collection of the Institute of Archaeology in Prague in Funds of the National Museum

Introduction	81
Department of Anthropology in the Institute of Archaeology and the origin of assortment	81
Resources of palaeopathological diagnostics	82
Characterization of the assortment of palaeopathological findings	83
The most important findings	83
Fate of the assortment of palaeopathological findings and prospects for their utilization	87
Acknowledgements	87
Survey of findings	87
Indices Index according to dating	103
Index according to localities	103
Index according to pathological conditions	104
References	105
Explanations of plates	107